

Pearls & Oy-sters: Status Epilepticus and Cerebral Edema From Hyperammonemia Due to Disseminated *Ureaplasma* and *Mycoplasma* Species

Suman Preet Bharath, MD, Haoming Pang, MD, Tamana Kaderi, MD, Reinaldo Rampolla, MD, Timothy Chen, MD, Michael Gezalian, MD, Shouri Lahiri, MD, Shahed Toossi, MD, and Maranatha Ayodele, MD

Neurology® 2023;100:727-731. doi:10.1212/WNL.0000000000206778

Correspondence

Dr. Bharath
suman.bharath@cshs.org

Abstract

Nonhepatic hyperammonemia syndrome is a rare cause of neurologic dysfunction and cerebral edema and has most commonly been reported in posttransplant patients. Only recently has opportunistic infection with *Ureaplasma* species and *Mycoplasma hominis* been found to be key to the pathogenesis. We describe the cases of 3 immunosuppressed patients who developed hyperammonemia syndrome with new-onset refractory status epilepticus and diffuse cerebral edema. PCR was positive for *M hominis* in 1 patient and *Ureaplasma parvum* in the other 2. Despite early diagnostic suspicion and aggressive management with empirical antibiotics, seizure control, hypertonic saline, and ammonia elimination, none of our patients survived this life-threatening infection. Nonhepatic hyperammonemia and new-onset seizures can be presenting features of disseminated *Ureaplasma* species and *M hominis* infections in posttransplant patients. Immunosuppression in the absence of organ transplantation is likely sufficient to trigger this entity, as was the case in our third patient. When suspected, empiric combination antibiotics should be used due to high likelihood of resistance. The diagnostic test of choice is PCR. Patients with hyperammonemia syndrome associated with these infections typically have a poor prognosis. Early recognition and aggressive multimodal interventions may be key to ameliorating the high mortality and severe neurologic sequelae from this entity.

Pearls

- Nonhepatic hyperammonemia and seizures can be presenting features of disseminated *Ureaplasma* and *Mycoplasma* infections.
- The diagnostic test of choice is PCR.

Oy-sters

- *Ureaplasma* and *Mycoplasma* infections may be underdiagnosed in immunosuppressed patients presenting with encephalopathy, seizures, cerebral edema, and hyperammonemia.
- Empiric combination antibiotics are recommended as there is high likelihood of resistance to a single agent.

Case Presentations

Patient 1

A 56-year-old man underwent bilateral orthotopic lung transplantation 7 days earlier. He then developed encephalopathy and gaze deviation concerning for seizure. He was on immunosuppression with tacrolimus, mycophenolate, and prednisone. Evaluation revealed an elevated ammonia level of 432 $\mu\text{mol/L}$ (reference range 18–72 $\mu\text{mol/L}$; the ammonia level 3 weeks prior was 36 $\mu\text{mol/L}$). He had no history of liver dysfunction, and liver function tests (LFTs) were normal. The initial head CT was unremarkable. He was afebrile with no leukocytosis. Continuous venovenous hemodiafiltration (CVVHD) and lactulose were initiated for

From the Department of Neurology (S.P.B., H.P., T.C., M.G., S.L., S.T., M.A.); Division of Pulmonary and Critical Care Medicine (T.K.), Cedars-Sinai Medical Center; and Division of Pulmonary and Critical Care Medicine (R.R.), Cedars-Sinai Comprehensive Transplant Center, Los Angeles, CA.

Go to [Neurology.org/N](https://www.neurology.org/N) for full disclosures. Funding information and disclosures deemed relevant by the authors, if any, are provided at the end of the article.

hyperammonemia management. There was concern for opportunistic infection with *Mycoplasma* and/or *Ureaplasma* spp., and serum PCR tests were sent. Antibiotic treatment with azithromycin was initiated empirically. The next day, he had recurrence of seizures. Despite treatment with lorazepam, levetiracetam, and lacosamide, he progressed to refractory status epilepticus (eFigure 1, links.lww.com/WNL/C574) requiring midazolam and ketamine infusions. Antibiotics were broadened to doxycycline and levofloxacin 24 hours postpresentation. Approximately 38 hours postpresentation, he had dramatic worsening. His neurologic examination was notable for unresponsiveness and absence of all brainstem reflexes. A repeat head CT revealed diffuse cerebral edema with complete loss of gray-white differentiation and obliteration of the basal cisterns. Despite hyperosmolar therapy and correction of the ammonia level to less than 90 $\mu\text{mol/L}$, his neurologic examination remained poor with the absence of all brainstem reflexes except initiation of spontaneous breaths. Following discussions with family, he was transitioned to comfort measures and died shortly after. PCR testing later resulted positive for *Mycoplasma hominis*.

Patient 2

A 59-year-old man status postorthotopic heart transplantation 7 weeks earlier developed acute encephalopathy. He was on immunosuppression with tacrolimus and prednisone. He was afebrile but had a leukocytosis attributed to pneumonia. Laboratory workup revealed an ammonia level of 810 $\mu\text{mol/L}$ (the ammonia level 3 days prior was 65 $\mu\text{mol/L}$). The initial head CT was normal. He subsequently developed seizures with left facial twitching and head jerking. He progressed to refractory status epilepticus (eFigure 1, links.lww.com/WNL/C574) requiring midazolam infusion. CVVHD, arginine, levocarnitine, lactulose, and rifaximin were initiated for ammonia clearance. There was concern for opportunistic infection with *Mycoplasma* and/or *Ureaplasma* spp., and serum PCR tests were sent. Antibiotic treatment with doxycycline was initiated empirically. Thirty-six hours postpresentation, he was noted with bilateral dilated and nonreactive pupils. A repeat head CT showed diffuse cerebral edema with sulcal effacement and crowding of the basal cisterns. Hyperosmolar therapy was initiated. His examination remained poor. Later that evening, he had a cardiac arrest and died. PCR testing resulted the following day confirming *Ureaplasma parvum* infection.

Patient 3

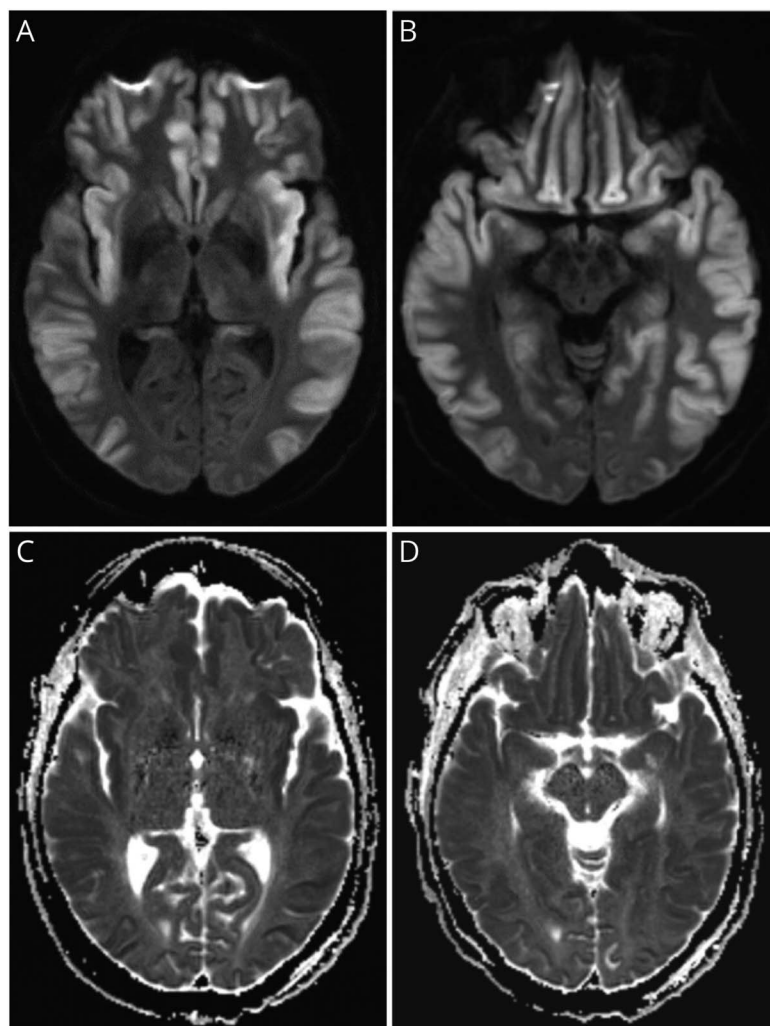
A 57-year-old man with dermatomyositis, seronegative rheumatoid arthritis, and interstitial lung disease on immunosuppression with methotrexate, leflunomide, prednisone, mycophenolate mofetil, and rituximab was admitted for septic arthritis. On day 4, he became acutely obtunded requiring intubation. Noncontrast head CT and CT angiogram were unrevealing. He had low-grade fevers and a mild leukocytosis attributed to septic arthritis. The ammonia level returned markedly elevated at 1,477 $\mu\text{mol/L}$. He had no prior history of liver dysfunction. LFTs were normal and

ammonia level about a month earlier was 15 $\mu\text{mol/L}$. CVVHD, lactulose, and rifaximin were initiated. There was concern for opportunistic infection with *Mycoplasma* and/or *Ureaplasma* spp., and serum PCR tests were sent. Antibiotic treatment with doxycycline was initiated empirically. Later that day, he developed seizures, which progressed to refractory status epilepticus (eFigure 1, links.lww.com/WNL/C574) requiring midazolam and ketamine infusions. A repeat head CT revealed diffuse cerebral edema. He was initiated on hyperosmolar therapy in addition to ongoing efforts for ammonia clearance. Ammonia levels fell to less than 90 $\mu\text{mol/L}$ by day 8. PCR testing for *U parvum* later resulted positive. He completed an 8-day course of doxycycline. Although seizures resolved, he remained severely encephalopathic. Brain MRI obtained on day 14 showed diffuse cortical diffusion restriction (Figure 1). Somatosensory evoked potentials revealed the presence of bilateral cortical N20 peaks. The family elected to allow time for neurologic recovery. His clinical course, however, was complicated by development of bowel ischemia and sepsis with multiorgan failure, and he died on day 26.

Discussion

Here, we describe 3 immunosuppressed patients, 2 of whom were post-solid organ transplantation, who developed encephalopathy, status epilepticus, and cerebral edema. They were then found with hyperammonemia in the absence of significant liver dysfunction. Nonhepatic hyperammonemia/hyperammonemia syndrome is a rare and often fatal cause of neurologic dysfunction and cerebral edema. The differential is broad and includes gastrointestinal bleeding, multiple myeloma, urea cycle disorders, and the adverse effects of certain medications.¹ It has been reported most commonly in posttransplant patients, especially after lung transplantation.²⁻⁹ Only recently has opportunistic infection with *Ureaplasma* spp. and *M hominis* been found to be key to the pathogenesis.^{5,6}

Ureaplasma spp. and *M hominis* are known benign, commensal urogenital organisms. Ammonia is generated as a consequence of their metabolic processes. Although this production is benign under normal circumstances, ammonia clearance becomes problematic when these organisms become widely disseminated. Such dissemination can occur in immunocompromised posttransplantation patients.⁴⁻⁷ Lung transplant patients are most frequently affected. This is postulated to be due to transmission of bacteria through donor lungs as additional respiratory tract colonization by these organisms has been described.^{2,7} *Ureaplasma* spp. use the urease enzyme to generate ATP via hydrolysis of urea into carbon dioxide and ammonia⁵ (Figure 2). *M hominis* produces energy through arginine degradation, which as well generates ammonia as a byproduct.¹⁰ There are additionally data showing that *Ureaplasma* spp. may disrupt the blood-brain barrier (BBB). This is hypothesized to be the mechanism by which *Ureaplasma* directly invades the CNS



Brain MRI diffusion-weighted imaging showing diffuse cortical diffusion restriction (A) and (B), with apparent diffusion coefficient correlate (C) and (D). Patient 3.

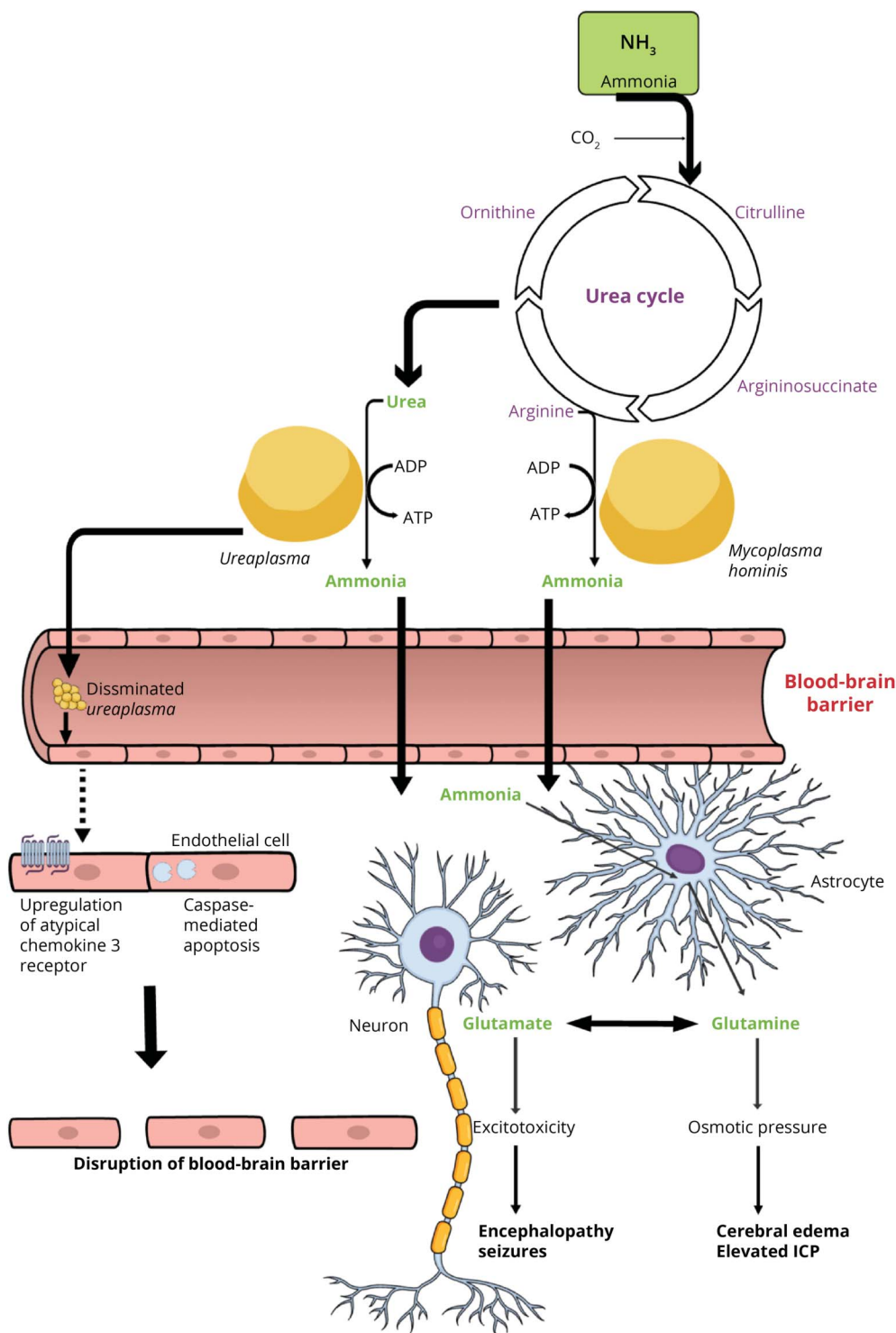
in neonatal meningitis.¹¹ Meningitis was considered in all our cases. However, a lumbar puncture was determined to be risky given the rapid development of cerebral edema and signs of elevated intracranial pressure. Whether breakdown of the BBB contributes to the rapid development of malignant cerebral edema remains unknown.

Diagnosis of these infections through serum PCR testing is preferable as this typically yields faster results.^{5,6,10} Lung transplantation patients may also have PCR of bronchioalveolar lavage or pleural fluid sent.⁷ Obtaining culture provides important information regarding antimicrobial susceptibility.⁵ However, culture is difficult to obtain as these are known fastidious organisms requiring use of specific enriched media.^{5,7,10} The ongoing ammonia generation by these organisms is postulated to make typical strategies aimed at ammonia clearance ineffective or insufficient. Additional use of antibiotics to cull the infections has been shown to be an important factor.^{5,9,10} Although *Ureaplasma* spp. are generally susceptible to fluoroquinolones, macrolides, and tetracyclines, resistance to each of these classes has also been

reported.^{5,10} *M hominis* notably has known resistance to macrolides.¹⁰ As such, combination antimicrobial therapy (i.e., tetracycline plus fluoroquinolone) is recommended as empiric treatment while awaiting sensitivity data from culture.¹⁰ All 3 of our patients were initially treated with a single antibiotic. Although our first patient was quickly broadened to a combination regimen, that was not the case for the other 2.

Typical MRI findings of hyperammonemia in adults have been reported as restricted diffusion and T2 fluid-attenuated inversion recovery (FLAIR) hyperintensity in the insular and cingulate cortices.¹² Other cortical areas may be involved to a variable degree. Only our third patient underwent MRI, which showed extensive diffuse cortical restricted diffusion and FLAIR hyperintensities (Figure 1). This cortical injury has been shown to be potentially reversible.¹² Sadly, all 3 of our patients had poor outcomes. Unfortunately, patients with hyperammonemia syndrome associated with these infections typically have a poor prognosis. A recently published systematic review and

Figure 2 Representation of Mechanisms of Ammonia Generation by *Ureaplasma* Spp. and *Mycoplasma hominis* and Pathophysiologic Consequences



meta-analysis⁷ found a 5-fold increased mortality rate among immunocompromised patients and transplant recipients with hyperammonemia syndrome associated with *Ureaplasma* spp. Early recognition and aggressive intervention to include combination antimicrobial therapy may nevertheless be key to ameliorating the high mortality

and severe neurologic sequelae from this entity. For hyperammonemia, we recommend an early, aggressive, multimodal approach as previously described in literature,⁸ which includes bowel decontamination, use of nitrogen scavengers, and intensive high-dose renal replacement therapy. Furthermore, we emphasize early aggressive

management of neurologic sequelae of seizures and cerebral edema.^{13,14}

These infections may be underdiagnosed in patients presenting with encephalopathy, seizures, cerebral edema, and hyperammonemia in the setting of organ transplantation or immunosuppression. Indeed, prior to discovery of the unique pathophysiologic contribution of these organisms, many cases likely went undiagnosed. Underdiagnosis may be particularly common in cases of immunosuppression without organ transplantation, as was the case in our third patient.¹⁵ A key clue is noting marked hyperammonemia in the absence of significant liver dysfunction. We hope that these cases raise awareness of this entity and recommend early initiation of empiric multimodal interventions. These should include empiric combination antimicrobial therapy, multimodal therapies aimed at ammonia clearance, and aggressive management of neurologic sequelae. We recommend PCR testing for prompt diagnosis. Culture data may also be pursued but should be expected to yield delayed results.

Study Funding

The authors report no targeted funding.

Disclosure

The authors report no disclosures relevant to the manuscript. Go to [Neurology.org/N](https://www.neurology.org/N) for full disclosures.

Publication History

Received by *Neurology* July 11, 2022. Accepted in final form November 18, 2022. Submitted and externally peer reviewed. The handling editor was Resident and Fellow Section Editor Whitley Aamodt, MD, MPH.

Appendix Authors

Name	Location	Contribution
Suman Preet Bharath, MD	Department of Neurology, Cedars-Sinai Medical Center, Los Angeles, CA	Drafting/revision of the manuscript for content, including medical writing for content; major role in the acquisition of data; study concept or design; analysis or interpretation of data; figures
Haoming Pang, MD	Department of Neurology, Cedars-Sinai Medical Center, Los Angeles, CA	Major role in the acquisition of data
Tamana Kaderi, MD	Division of Pulmonary and Critical Care Medicine, Cedars-Sinai Medical Center, Los Angeles, CA	Major role in the acquisition of data
Reinaldo Rampolla, MD	Division of Pulmonary and Critical Care Medicine, Cedars-Sinai Comprehensive Transplant Center, Los Angeles, CA	Drafting/revision of the manuscript for content, including medical writing for content

Appendix (continued)

Name	Location	Contribution
Timothy Chen, MD	Department of Neurology, Cedars-Sinai Medical Center, Los Angeles, CA	Major role in the acquisition of data; EEG images
Michael Gezalian, MD	Department of Neurology, Cedars-Sinai Medical Center, Los Angeles, CA	Drafting/revision of the manuscript for content, including medical writing for content
Shouri Lahiri, MD	Department of Neurology, Cedars-Sinai Medical Center, Los Angeles, CA	Drafting/revision of the manuscript for content, including medical writing for content
Shahed Toossi, MD	Department of Neurology, Cedars-Sinai Medical Center, Los Angeles, CA	Drafting/revision of the manuscript for content, including medical writing for content
Maranatha Ayodele, MD	Department of Neurology, Cedars-Sinai Medical Center, Los Angeles, CA	Drafting/revision of the manuscript for content, including medical writing for content; major role in the acquisition of data; study concept or design; analysis or interpretation of data

References

- Long MT, Coursin DB. Undifferentiated non-hepatic hyperammonemia in the ICU: diagnosis and management. *J Crit Care.* 2022;70:154042.
- Matson KM, Sonetti DA. Successful treatment of *Ureaplasma*-induced hyperammonemia syndrome post-lung transplant. *Transpl Infect Dis.* 2019;21(1):e13022.
- Graetz R, Meyer R, Shehab K, Katsanis E. Successful resolution of hyperammonemia following hematopoietic cell transplantation with directed treatment of *Ureaplasma parvum* infection. *Transpl Infect Dis.* 2018;20(2):e12839.
- Tawfik P, Arndt P. Lethal hyperammonemia in a CAR-T cell recipient due to *Ureaplasma pneumoniae*: a case report of a unique severe complication. *BMJ Case Rep.* 2021;14(7):e242513.
- Bharat A, Cunningham SA, Scott Budinger GR, et al. Disseminated *Ureaplasma* infection as a cause of fatal hyperammonemia in humans. *Sci Transl Med.* 2015;7(284):284re3.
- Wylam ME, Kennedy CC, Hernandez NM, et al. Fatal hyperammonemia caused by *Mycoplasma hominis*. *Lancet.* 2013;382(9908):1956.
- Tantengco OAG, De Jesus FCC II, Gampoy EFS, Ornos EDB, Vidal MS Jr., Abad CLR. Hyperammonemia syndrome associated with *Ureaplasma* spp. infections in immunocompromised patients and transplant recipients: a systematic review and meta-analysis. *Clin Transpl.* 2021;35(7):e14334.
- Krutsinger D, Pezzulo A, Blevins AE, Reed RM, Voigt MD, Eberlein M. Idiopathic hyperammonemia after solid organ transplantation: primarily a lung problem? A single-center experience and systematic review. *Clin Transpl.* 2017;31(5):e12957.
- Legouy C, Hu A, Mochel F, et al. *Ureaplasma parvum* causes hyperammonemia presenting as refractory status epilepticus after kidney transplant. *J Crit Care.* 2020;57:79-83.
- Nowbakht C, Edwards AR, Rodriguez-Buritica DF, et al. Two cases of fatal hyperammonemia syndrome due to *Mycoplasma hominis* and *Ureaplasma urealyticum* in immunocompromised patients outside lung transplant recipients. *Open Forum Infect Dis.* 2019;6(3):ofz033.
- Silwedel C, Haarmann A, Fehrholz M, Claus H, Speer CP, Glaser K. More than just inflammation: *Ureaplasma* species induce apoptosis in human brain microvascular endothelial cells. *J Neuroinflammation.* 2019;16(1):38.
- U-King-Im JM, Yu E, Bartlett E, Soobrah R, Kucharczyk W. Acute hyperammonemic encephalopathy in adults: imaging findings. *AJNR Am J Neuroradiol.* 2011;32(2):413-418.
- Canalese J, Gimson AE, Davis C, Mellon PJ, Davis M, Williams R. Controlled trial of dexamethasone and mannitol for the cerebral oedema of fulminant hepatic failure. *Gut.* 1982;23(7):625-629.
- Murphy N, Auzinger G, Bernel W, Wendon J. The effect of hypertonic sodium chloride on intracranial pressure in patients with acute liver failure. *Hepatology.* 2004;39(2):464-470.
- Placone N, Kao RL, Kempert P, et al. Hyperammonemia from *Ureaplasma* infection in an immunocompromised child. *J Pediatr Hematol Oncol.* 2020;42(2):e114-e116.

Neurology®

Pearls & Oysters: Status Epilepticus and Cerebral Edema From Hyperammonemia Due to Disseminated *Ureaplasma* and *Mycoplasma* Species

Suman Preet Bharath, Haoming Pang, Tamana Kaderi, et al.

Neurology 2023;100;727-731 Published Online before print December 23, 2022

DOI 10.1212/WNL.0000000000206778

This information is current as of December 23, 2022

Updated Information & Services	including high resolution figures, can be found at: http://n.neurology.org/content/100/15/727.full
References	This article cites 15 articles, 3 of which you can access for free at: http://n.neurology.org/content/100/15/727.full#ref-list-1
Permissions & Licensing	Information about reproducing this article in parts (figures, tables) or in its entirety can be found online at: http://www.neurology.org/about/about_the_journal#permissions
Reprints	Information about ordering reprints can be found online: http://n.neurology.org/subscribers/advertise

Neurology® is the official journal of the American Academy of Neurology. Published continuously since 1951, it is now a weekly with 48 issues per year. Copyright © 2022 American Academy of Neurology. All rights reserved. Print ISSN: 0028-3878. Online ISSN: 1526-632X.

