

Clinical Reasoning: A 12-Year-Old Girl With Acute-Onset Diplopia, Dizziness, and Upbeat Nystagmus

Gaurav Chenji, MD, Mark Phillips Figgie, MD, Monica Rondinelli, MD, Hemani Ticku, MD, and Neel Fotedar, MD

Neurology® 2023;100:301-306. doi:10.1212/WNL.0000000000201534

Correspondence

Dr. Fotedar
neel.fotedar@
uhhospitals.org

Abstract

We report a case of a 12-year-old girl who presented with acute-onset diplopia, dizziness, and upbeat nystagmus. On examination, she had right internuclear ophthalmoplegia with right eye hypertropia and exotropia and impaired convergence. In addition, she also had spontaneous primary position symmetric upbeat nystagmus. In this report, we discuss the clinical approach with meticulous neuro-ophthalmologic examination and neuroanatomic localization in pediatric patients with acute-onset diplopia.

From the Neurological Institute (G.C., M.P.F., H.T., N.F.), University Hospitals Cleveland Medical Center; Department of Neurology (G.C., M.P.F., H.T., N.F.), Case Western Reserve University School of Medicine, Cleveland; and Department of Pediatrics (M.R.), Rainbow Babies and Children's Hospital, Cleveland, OH.

Go to [Neurology.org/N](https://www.neurology.org/N) for full disclosures. Funding information and disclosures deemed relevant by the authors, if any, are provided at the end of the article.

Section 1

A 12-year-old girl with a history of asthma presented with acute-onset diplopia, dizziness, and abnormal eye movements. She described the diplopia as images stacked side to side. The diplopia disappeared on closing either eye and was worse on leftward gaze. She reported a subjective feeling of dizziness and described her eyes as going crazy. She denied headache, pain with eye movements, weakness, and bowel or bladder symptoms. There was no preceding illness or trauma.

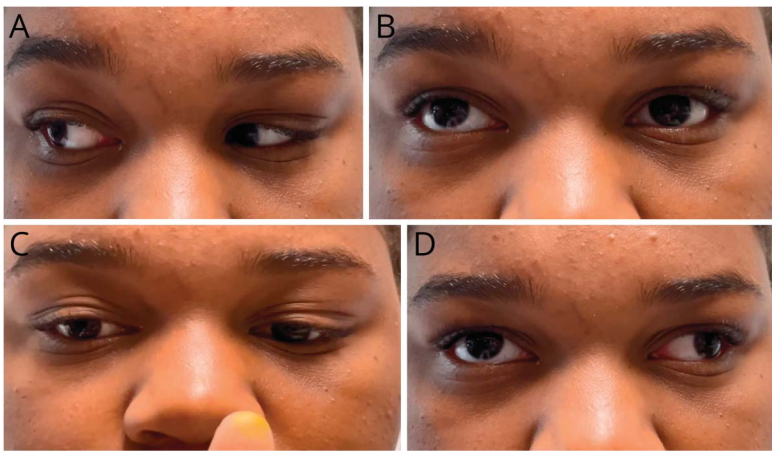
Examination revealed exotropia and hypertropia of the right eye in the primary position. There was adduction paresis of the right eye on leftward conjugate gaze with dissociated abducting nystagmus of the left eye. There was no adduction

deficit with rightward conjugate gaze (Figure 1). The vertical misalignment was comitant in all directions. This was associated with a subtle clockwise (top poles beating to the right) torsional nystagmus, best seen in rightward conjugate gaze and downward gaze. Prominent symmetric upbeat nystagmus was present in primary gaze, which increased significantly in upgaze. Convergence of the right eye was impaired as well (Figure 1). Visual acuity with correction was normal. The remainder of the neurologic examination was normal. A limitation of our study is that we did not quantify the ocular deviations using prisms.

Questions for Consideration:

1. What is the localization of this neuro-ophthalmologic presentation?
2. What is the significance of impaired convergence?

Figure 1 Neuro-ophthalmologic Examination



(A) Intact rightward conjugate gaze. (B) Primary position showing right eye hypertropia and exotropia. (C) Impaired right eye convergence. (D) Attempted leftward conjugate gaze showing right eye adduction paresis.

GO TO SECTION 2

Section 2

The adduction paresis of the right eye with dissociated abducting nystagmus of the left eye on leftward conjugate gaze is consistent with right internuclear ophthalmoplegia (INO). This localizes to the right medial longitudinal fasciculus (MLF).¹ The comitant hypertropia of the right eye (skew deviation) with a clockwise torsional nystagmus are components of the ocular tilt reaction (OTR).¹ These findings are also consistent with a lesion of the right MLF. Another limitation of our study is that we did not confirm the cyclotorsion of eyes by fundoscopy.

Convergence may or may not be impaired in patients with INO.¹ It is generally considered that intact convergence

with INO (Cogan posterior INO) is consistent with a more caudal lesion of the MLF, whereas impaired convergence (Cogan anterior INO) is consistent with a more rostral lesion of the MLF.¹ Therefore, the lesion is most likely located in the right medial and dorsal brainstem, anywhere between the caudal pons and the rostral midbrain. The lack of convergence points toward a more rostral lesion.

Questions for Consideration:

1. What is the significance of upbeat nystagmus?
2. What is the localization of INO, impaired convergence, and upbeat nystagmus?

GO TO SECTION 3

Section 3

Upbeat nystagmus, present in primary gaze, is characterized by slow downward phase and quick upward phase. It has the highest amplitude in upgaze, and it does not increase much in lateral gaze.¹ Unlike downbeat nystagmus, upbeat nystagmus is less well localized. In most cases, upbeat nystagmus localizes to the caudal medulla, but cases with more rostral brainstem lesions have also been reported.¹ These rostral brainstem lesions are located at the junction of the rostral pons and caudal midbrain.¹⁻³

So far, we have localized the right INO and skew deviation to the right MLF in the rostral brainstem. The addition of upbeat nystagmus further localizes the lesion to the junction of the rostral pons and caudal midbrain on the right side in the dorsomedial region.¹⁻³

Question for Consideration:

1. What are the differential diagnoses for this neuro-ophthalmologic presentation in children?

GO TO SECTION 4

Section 4

Most adult cases of INO are related to brainstem ischemia and demyelinating disorders like multiple sclerosis.^{1,4} INO is relatively poorly described in children, and some of the common causes reported are brainstem tumors like gliomas and medulloblastomas, trauma, and hemorrhage.⁴ Ischemic strokes, being uncommon in children, have only been reported to cause INO in patients with sickle cell disease, lupus, Fabry disease, and so on.⁴ Bilateral INO of subacute onset in adults and children is mostly related to demyelinating diseases.^{1,4}

This patient's brain MRI showed a small area of diffusion restriction at the junction of the medial midbrain and pons in the dorsal region on the right side (eFigure 1, links.lww.com/WNL/C472). No other lesions suggestive of a demyelinating nature were seen.

Her intracranial and extracranial vascular imaging did not reveal any abnormalities. Her hypercoagulable workup was negative as well. The echocardiogram showed a patent foramen ovale (PFO). She was placed on daily aspirin 81 mg and was referred for PFO closure. She had complete resolution of her symptoms at follow-up 8 weeks later.

Discussion

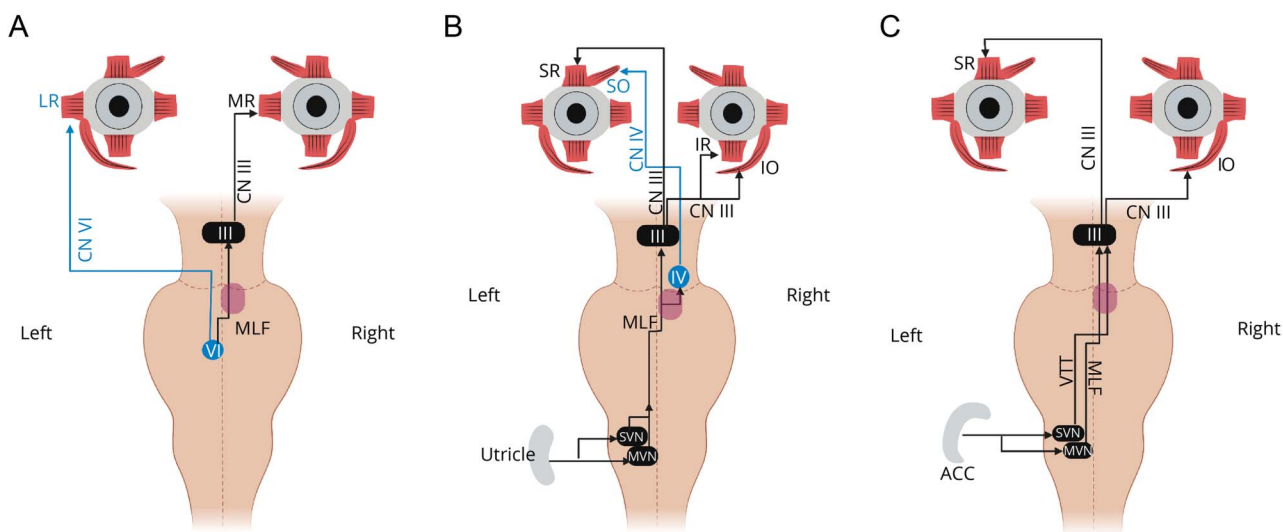
Weakness of adduction of one eye with attempted conjugate horizontal gaze is characteristic of INO, which is caused by a lesion

of the MLF on the side of adduction paresis. The descending conjugate gaze command from the abducens nucleus interneurons is relayed to the oculomotor nucleus motor neurons, on the other side, via the MLF (Figure 2A). Thus, a lesion of the MLF leads to either complete adduction paresis or adduction lag of the ipsilateral eye.¹ The other cardinal feature of INO is dissociated abducting nystagmus of the contralateral eye. Because of the weakness of the adducting eye, there is an increase in innervation to the medial rectus subnucleus to get the adducting eye to target. There is a concurrent increase in the innervation of the normal abducting eye (because of the Hering law of equal innervation), hence leading to overshoot of the saccades, followed by backward postsaccadic drifts. This saccadic oscillation appears as nystagmus.¹

Skew deviation commonly occurs with INO and is the most likely cause of vertical misalignment in such patients.^{1,5} Skew deviation is a component of the OTR, along with torsional nystagmus, and it is related to the interruption of the central otolithic pathway, mediating the vestibulo-ocular reflex (VOR) in the roll plane.⁵ This pathway carries signals from the utricle to the medial vestibular nucleus and superior vestibular nucleus (SVN). These nuclei, in turn, project to the oculomotor and trochlear nuclei via the MLF (Figure 2B).^{1,5} A rostral MLF lesion causes the ipsilateral eye to be hypertropic.^{1,5} Hence, in most cases of INO with skew deviation, the eye with adduction paresis is also elevated compared with the other eye.¹

Convergence may or may not be impaired in patients with INO. Generally, it is believed that intact convergence

Figure 2 Neuroanatomic Schematic



(A) Horizontal leftward conjugate gaze brainstem pathway. (B) Otolithic pathway for leftward head tilt. (C) Anterior semicircular canal VOR pathway. The pink oval shaded region at the right medial pontomesencephalic junction shows the location of the lesion. In (A), this lesion affects the MLF, causing right INO. In (B), the lesion affects MLF, carrying otolithic signals from the left utricle, thus producing right eye hypertropia (skew deviation) with cyclotorsion to the left (SR and SO would normally intort the left eye; IR and IO would normally extort the right eye) and rightward torsional nystagmus (OTR). In (C), the lesion affects both MLF and VTT, carrying signals from the ACC, thus producing a downward bias (by affecting the left SR and right IO muscles) and an upbeat nystagmus. ACC = anterior semicircular canal; CN = cranial nerve; IO = inferior oblique; LR = lateral rectus; MLF = medial longitudinal fasciculus; MR = medial rectus; MVN = medial vestibular nucleus; SO = superior oblique; SR = superior rectus; SVN = superior vestibular nucleus; VTT = ventral tegmental tract; III = oculomotor nucleus; IV = trochlear nucleus; VI = abducens nucleus. This figure was created with BioRender.com.

indicates a more caudal brainstem lesion and impaired convergence indicates a more rostral brainstem lesion.¹ This explanation indicates that impaired convergence is caused by either direct involvement of the medial rectus subnucleus of the oculomotor complex or because of the involvement of the convergence center in the dorsal midbrain.¹ Exotropia may be present with or without impaired convergence as well. Furthermore, exotropia in patients with INO does not necessarily imply involvement of the medial rectus subnucleus.^{1,3} Hence, a lack of convergence with or without exotropia may have some localizing significance, but experts caution against using only this factor in localizing INO.¹

Different types of vertical/torsional nystagmus have been described in patients with INO.^{1,6,7} The majority of patients with INO also have some elements of OTR (skew deviation, torsional nystagmus, and head tilt). This is because of the common involvement of the MLF.^{1,6,7} Hence, many patients with INO have a torsional nystagmus with the top poles beating toward the side of the lesion.^{1,6} Dissociated vertical-torsional nystagmus has been described in patients with INO. The most common pattern is an ipsilesional conjugate torsional nystagmus with an asymmetric upbeat nystagmus, with the larger upbeat component in the contralesional eye.⁶ Pure upbeat nystagmus is rarely reported in patients with INO.^{2,3} There are 2 potential explanations for pure upbeat nystagmus. The excitatory signals from the anterior semicircular canal being relayed from the SVN are partly conducted via an extra-MLF pathway known as the ventral tegmental tract. This tract is more ventral in the pontine tegmentum and decussates in the midpons, after which it ascends more medially till it reaches the superior rectus and inferior oblique motor neurons in the oculomotor complex (Figure 2C).⁷ An MLF lesion extending to this pathway could create a downward bias, hence leading to an upbeat nystagmus.^{1-3,7} The second mechanism suggests that the descending projections from the interstitial nucleus of Cajal (vertical and torsional gaze neural integrator) toward the cerebellum and medullary nucleus of Roller travel via the paramedian tracts and a lesion of these pathways could lead to upbeat nystagmus due to integrator failure.^{1-3,7}

Regardless of the exact mechanism, this unique combination of INO with exotropia, impaired convergence, and symmetric upbeat nystagmus reliably localizes to the dorsomedial pontomesencephalic junction.³ This presentation has been reported in adults with bilateral or unilateral INO.¹⁻³ The most likely diagnosis in our patient was an acute infarct related to a large PFO.

Study Funding

The authors report no targeted funding.

Disclosure

The authors report no relevant disclosures. Go to Neurology.org/N for full disclosures.

Publication History

Received by *Neurology* July 21, 2022. Accepted in final form September 23, 2022. Submitted and externally peer reviewed. The handling editor was Katherine Fu, MD.

Appendix Authors

Name	Location	Contribution
Gaurav Chenji, MD	Neurological Institute, University Hospitals Cleveland Medical Center, Cleveland, OH; Department of Neurology, Case Western Reserve University School of Medicine, Cleveland, OH	Drafting/revision of the manuscript for content, including medical writing for content; major role in the acquisition of data; study concept or design; and analysis or interpretation of data
Mark Phillips Figgie, MD	Neurological Institute, University Hospitals Cleveland Medical Center, Cleveland, OH; Department of Neurology, Case Western Reserve University School of Medicine, Cleveland, OH	Major role in the acquisition of data and analysis or interpretation of data
Monica Rondinelli, MD	Department of Pediatrics, Rainbow Babies and Children's Hospital, Cleveland, OH	Major role in the acquisition of data; study concept or design; and analysis or interpretation of data
Hemani Ticku, MD	Neurological Institute, University Hospitals Cleveland Medical Center, Cleveland, OH; Department of Neurology, Case Western Reserve University School of Medicine, Cleveland, OH	Drafting/revision of the manuscript for content, including medical writing for content, and major role in the acquisition of data
Neel Fotedar, MD	Neurological Institute, University Hospitals Cleveland Medical Center, Cleveland, OH; Department of Neurology, Case Western Reserve University School of Medicine, Cleveland, OH	Drafting/revision of the manuscript for content, including medical writing for content; study concept or design; and analysis or interpretation of data

References

1. Leigh RJ, Zee DS. *The Neurology of Eye Movements*. 5th ed Oxford University press; 2015.
2. Choi JH, Jung NY, Kim MJ, Choi KD, Kim JS, Jung DS. Pure upbeat nystagmus in association with bilateral internuclear ophthalmoplegia. *J Neurol Sci*. 2012;317(1-2):148-150. doi: 10.1016/j.jns.2012.02.036
3. Shaikh AG, Ghasia FF, Rasouli G, DeGeorgia M, Sundararajan S. Acute onset of upbeat nystagmus, exotropia, and internuclear ophthalmoplegia—a tell-tale of ponto-mesencephalic infarct. *J Neurol Sci*. 2013;332(1-2):56-58. doi: 10.1016/j.jns.2013.06.012
4. Rizzo JL, Lloyd M, O'Hara MA. Pediatric internuclear ophthalmoplegia. *J Neuroophthalmol*. 2013;33(2):134-136. doi: 10.1097/WNO.0b013e3182881ad7
5. Fotedar N, Dong J, Lewis A, Devereaux M, Serra A. Clinical reasoning: a 45-year-old man with vertical diplopia. *Neurology*. 2022;98(2):82-87. doi: 10.1212/WNL.0000000000012999
6. Jeong SH, Kim EK, Lee J, Choi KD, Kim JS. Patterns of dissociate torsional-vertical nystagmus in internuclear ophthalmoplegia. *Ann N Y Acad Sci*. 2011;1233:271-278. doi: 10.1111/j.1749-6632.2011.06155.x
7. Pierrot-Deseilligny C, Milea D. Vertical nystagmus: clinical facts and hypotheses. *Brain*. 2005;128(Pt 6):1237-1246. doi:10.1093/brain/awh532

Neurology®

Clinical Reasoning: A 12-Year-Old Girl With Acute-Onset Diplopia, Dizziness, and Upbeat Nystagmus

Gaurav Chenji, Mark Phillips Figgie, Monica Rondinelli, et al.
Neurology 2023;100:301-306 Published Online before print November 8, 2022
DOI 10.1212/WNL.0000000000201534

This information is current as of November 8, 2022

Updated Information & Services	including high resolution figures, can be found at: http://n.neurology.org/content/100/6/301.full
References	This article cites 6 articles, 1 of which you can access for free at: http://n.neurology.org/content/100/6/301.full#ref-list-1
Subspecialty Collections	This article, along with others on similar topics, appears in the following collection(s): All Cerebrovascular disease/Stroke http://n.neurology.org/cgi/collection/all_cerebrovascular_disease_stroke Childhood stroke http://n.neurology.org/cgi/collection/childhood_stroke Diplopia (double vision) http://n.neurology.org/cgi/collection/diplopia_double_vision Nystagmus http://n.neurology.org/cgi/collection/nystagmus Oscillopsia http://n.neurology.org/cgi/collection/oscillopsia
Permissions & Licensing	Information about reproducing this article in parts (figures, tables) or in its entirety can be found online at: http://www.neurology.org/about/about_the_journal#permissions
Reprints	Information about ordering reprints can be found online: http://n.neurology.org/subscribers/advertise

Neurology® is the official journal of the American Academy of Neurology. Published continuously since 1951, it is now a weekly with 48 issues per year. Copyright © 2022 American Academy of Neurology. All rights reserved. Print ISSN: 0028-3878. Online ISSN: 1526-632X.

