

Teaching NeuroImage: Cerebellar Atrophy Due to JC Virus Granule Cell Neuronopathy

A Clinical Syndrome Distinct From Classic PML

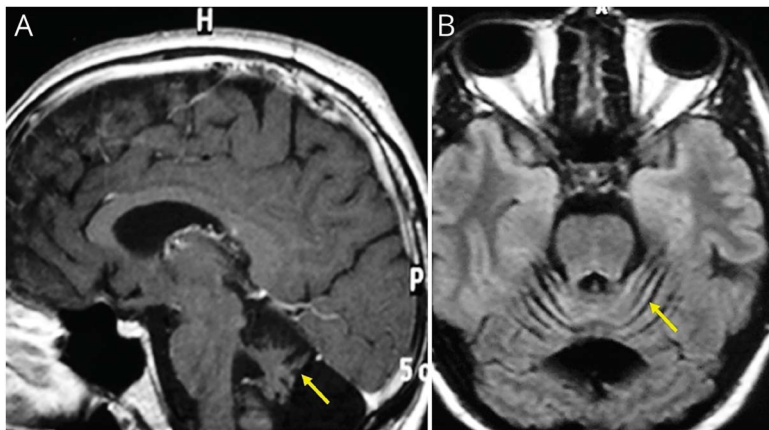
Carlos Silva-Rosas, MD, Gabriel Abudinén, MD, Alonso Quijada-Riquelme, MD, and Heather Angus-Leppan, MBBS (Hons), MSc, MD, FRACP, FRCP

Neurology® 2023;101:e343-e344. doi:10.1212/WNL.0000000000207155

Correspondence

Dr. Silva-Rosas
csilros@uchile.cl

Figure (A) Sagittal T1-Weighted Brain MRI and (B) Axial Fluid-Attenuated Inversion Recovery-Weighted Brain MRI Show Marked Cerebellar Atrophy (Arrows)



A 34-year-old Hispanic man with HIV infection on no treatment (CD4 20/ μ L, viral load 1.9/ 10^6 copies/mL) presented with 4 months of dizziness, ataxia, and scanning speech consistent with a pancerebellar syndrome. MRI scan (Figure) demonstrated marked cerebellar atrophy. CSF showed normal cell count, protein, and glucose levels, nonreactive venereal disease research laboratory test. CSF PCR was negative for cytomegalovirus, varicella-zoster, herpes simplex type 1 and 2, Epstein-Barr, and herpes virus 6, but positive for John Cunningham (JC) virus. JC virus granule cell neuronopathy (GCN) was diagnosed. JC virus variants may rarely infect cerebellar granule neurons instead of oligodendrocytes as seen in classic progressive multifocal leukoencephalopathy with white matter involvement.^{1,2} HAART (zidovudine, lamivudine, and efavirenz) commenced immediately, with slight symptomatic improvement at 12 months, MRI scan was unchanged. Clinicians should suspect JC virus strain infection producing GCN in AIDS patients with symptomatic cerebellar atrophy² and commence HAART promptly—immune reconstitution inflammatory syndrome is not usually a concern in cases of isolated JC virus GCN.

Author Contributions

C. Silva-Rosas: drafting/revision of the manuscript for content, including medical writing for content; major role in the acquisition of data; study concept or design; analysis or interpretation of data. G. Abudinén: study concept or design; analysis or interpretation of data. A. Quijada-Riquelme: study concept or design; analysis or interpretation of data. H. Angus-Leppan: study concept or design; analysis or interpretation of data.

*These authors contributed equally to this work.

From the Department of Neurology & Neurosurgery (C.S.-R., G.A., A.Q.-R.), Clinical Hospital of University of Chile, Santiago de Chile; Royal Free London NHS Foundation Trust (H.A.-L.); and Department of Clinical and Movement Neurosciences (H.A.-L.), UCL Queen Square Institute of Neurology, United Kingdom.

Go to [Neurology.org/N](https://www.neurology.org/N) for full disclosures. Funding information and disclosures deemed relevant by the authors, if any, are provided at the end of the article.

MORE ONLINE

Teaching slides

links.lww.com/WNL/C655

Study Funding

No targeted funding reported.

Disclosure

The authors report no relevant disclosures. Go to [Neurology.org/N](https://www.neurology.org/N) for full disclosures.

Publication History

Received by *Neurology* October 19, 2022. Accepted in final form January 20, 2023. Submitted and externally peer reviewed. The handling editor was Resident and Fellow Section Editor Whitley Aamodt, MD, MPH.

Appendix Authors

| Name | Location | Contribution |
|-------------------------------|---|--|
| Carlos Silva-Rosas, MD | Department of Neurology & Neurosurgery, Clinical Hospital of University of Chile, Santiago de Chile | Drafting/revision of the manuscript for content, including medical writing for content; major role in the acquisition of data; study concept or design; and analysis or interpretation of data |

Appendix (continued)

| Name | Location | Contribution |
|--|--|--|
| Gabriel Abudín, MD | Department of Neurology & Neurosurgery, Clinical Hospital of University of Chile, Santiago de Chile | Study concept or design and analysis or interpretation of data |
| Alonso Quijada-Riquelme, MD | Department of Neurology & Neurosurgery, Clinical Hospital of University of Chile, Santiago de Chile | Study concept or design and analysis or interpretation of data |
| Heather Angus-Leppan, MBBS (Hons), MSc, MD, FRACP, FRCP | Royal Free London NHS Foundation Trust; Department of Clinical and Movement Neurosciences, UCL Queen Square Institute of Neurology, United Kingdom | Study concept or design and analysis or interpretation of data |

References

1. Koralnik IJ, Wüthrich C, Dang X, et al. JC virus granule cell neuronopathy: a novel clinical syndrome distinct from progressive multifocal leukoencephalopathy. *Ann Neurol*. 2005;57(4):576-580. doi:10.1002/ana.20431.
2. Bernard-Valnet R, Koralnik IJ, Du Pasquier R. Advances in treatment of progressive multifocal leukoencephalopathy. *Ann Neurol*. 2021;90(6):865-873. doi:10.1002/ana.26198.

Neurology®

Teaching NeuroImage: Cerebellar Atrophy Due to JC Virus Granule Cell Neuronopathy: A Clinical Syndrome Distinct From Classic PML

Carlos Silva-Rosas, Gabriel Abudinén, Alonso Quijada-Riquelme, et al.
Neurology 2023;101:e343-e344 Published Online before print February 20, 2023
DOI 10.1212/WNL.0000000000207155

This information is current as of February 20, 2023

| | |
|---|--|
| Updated Information & Services | including high resolution figures, can be found at: http://n.neurology.org/content/101/3/e343.full |
| References | This article cites 2 articles, 0 of which you can access for free at: http://n.neurology.org/content/101/3/e343.full#ref-list-1 |
| Subspecialty Collections | This article, along with others on similar topics, appears in the following collection(s): HIV http://n.neurology.org/cgi/collection/hiv MRI http://n.neurology.org/cgi/collection/mri Viral infections http://n.neurology.org/cgi/collection/viral_infections |
| Permissions & Licensing | Information about reproducing this article in parts (figures, tables) or in its entirety can be found online at: http://www.neurology.org/about/about_the_journal#permissions |
| Reprints | Information about ordering reprints can be found online: http://n.neurology.org/subscribers/advertise |

Neurology® is the official journal of the American Academy of Neurology. Published continuously since 1951, it is now a weekly with 48 issues per year. Copyright © 2023 American Academy of Neurology. All rights reserved. Print ISSN: 0028-3878. Online ISSN: 1526-632X.

