

# Teaching NeuroImage: Low-Frequency Photoparoxysmal Response in a Patient With Neuronal Ceroid Lipofuscinosis Type 2

Amytice Mirchi, MD, and Kenneth A. Myers, MD, PhD

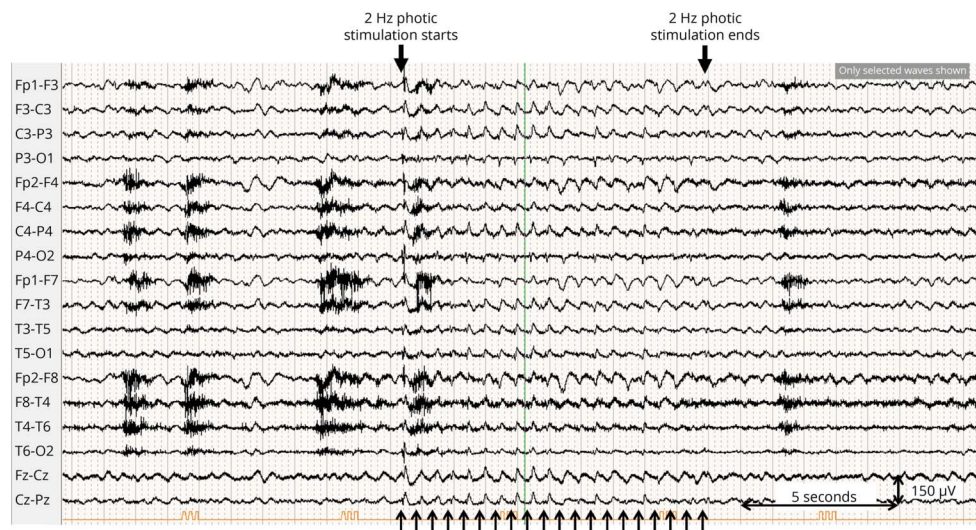
*Neurology*® 2023;101:e459-e460. doi:10.1212/WNL.0000000000207271

**Correspondence**

Dr. Myers

kenneth.myers@mcgill.ca

**Figure** Longitudinal Bipolar Montage EEG During Photic Stimulation



Light flash timing is shown at the bottom of the figure. During 2 Hz stimulation, grade 4 photoparoxysmal response is seen (spike-wave discharges maximal over posterior head regions). Spike-wave activity increased during the remainder of photic stimulation but was less clearly time locked to light flashes.

A 17-year-old man with neuronal ceroid lipofuscinosis (NCL) type 2 (CLN2) had an EEG. Photoparoxysmal response (PPR) was seen at 2 Hz (Figure). PPR refers to generalized spike-wave discharges elicited by intermittent photic stimulation (IPS) and may occur in epilepsy syndromes including juvenile myoclonic epilepsy and Dravet syndrome.<sup>1,2</sup> However, low-frequency (<5 Hz) PPR (LFPPR) is only reported in a few conditions, including Lafora disease, mitochondrial disorders, Creutzfeldt-Jakob disease, and NCL, most frequently CLN2, CLN5, and CLN6.<sup>1,2</sup> NCL is a group of progressive neurodegenerative disorders characterized by developmental impairment, cognitive decline, seizures, progressive visual impairment, and motor dysfunction. Neuroimaging features include progressive cerebral and cerebellar atrophy and thalamic and periventricular white matter signal abnormalities. IPS is an important test as identification of LFPPR could enable early NCL diagnosis, which is critical given that early administration of enzyme replacement therapy can reduce the rate of disease progression.

## Study Funding

The authors report no targeted funding.

## MORE ONLINE

### Teaching slides

[links.lww.com/WNL/C740](https://links.lww.com/WNL/C740)

From the Department of Pediatrics (A.M., K.A.M.), Division of Child Neurology, Montreal Children's Hospital; Department of Neurology and Neurosurgery (A.M., K.M.); and Research Institute of the McGill University Health Centre (K.M.), Montreal, Canada.

Go to [Neurology.org/N](https://Neurology.org/N) for full disclosures. Funding information and disclosures deemed relevant by the authors, if any, are provided at the end of the article.

## Disclosure

The authors report no relevant disclosures. Go to [Neurology.org/N](https://www.neurology.org/N) for full disclosures.

## Author Contributions

A. Mirchi: drafting/revision of the manuscript for content, including medical writing for content; major role in the acquisition of data; study concept or design; analysis or interpretation of data. K. Myers: drafting/revision of the manuscript for content, including medical writing for content; major role in the acquisition of data; study concept or design; analysis or interpretation of data.

## Publication History

Received by *Neurology* October 29, 2022. Accepted in final form February 22, 2023. Submitted and externally peer reviewed. The handling editor was Resident & Fellow Deputy Editor Ariel Lyons-Warren, MD, PhD.

## References

1. Albert DV, Yin H, De Los Reyes EC, Vidaurre J. Unique characteristics of the photoparoxysmal response in patients with neuronal ceroid lipofuscinosis type 2: can EEG be a biomarker? *J Child Neurol*. 2016;31(13):1475-1482. doi: 10.1177/0883073816658659
2. Trivisano M, Ferretti A, Calabrese C, et al. Neurophysiological findings in neuronal ceroid lipofuscinoses. *Front Neurol*. 2022;13:845877. doi: 10.3389/fneur.2022.845877

# Neurology®

## Teaching NeuroImage: Low-Frequency Photoparoxysmal Response in a Patient With Neuronal Ceroid Lipofuscinosis Type 2

Amytice Mirchi and Kenneth A. Myers

*Neurology* 2023;101:e459-e460 Published Online before print April 17, 2023

DOI 10.1212/WNL.0000000000207271

**This information is current as of April 17, 2023**

<b>Updated Information &amp; Services</b>	including high resolution figures, can be found at: <a href="http://n.neurology.org/content/101/4/e459.full">http://n.neurology.org/content/101/4/e459.full</a>
<b>References</b>	This article cites 2 articles, 0 of which you can access for free at: <a href="http://n.neurology.org/content/101/4/e459.full#ref-list-1">http://n.neurology.org/content/101/4/e459.full#ref-list-1</a>
<b>Subspecialty Collections</b>	This article, along with others on similar topics, appears in the following collection(s): <b>All Genetics</b> <a href="http://n.neurology.org/cgi/collection/all_genetics">http://n.neurology.org/cgi/collection/all_genetics</a> <b>EEG; see Epilepsy/Seizures</b> <a href="http://n.neurology.org/cgi/collection/eeg_see_epilepsy-seizures">http://n.neurology.org/cgi/collection/eeg_see_epilepsy-seizures</a> <b>Metabolic disease (inherited)</b> <a href="http://n.neurology.org/cgi/collection/metabolic_disease_inherited">http://n.neurology.org/cgi/collection/metabolic_disease_inherited</a>
<b>Permissions &amp; Licensing</b>	Information about reproducing this article in parts (figures, tables) or in its entirety can be found online at: <a href="http://www.neurology.org/about/about_the_journal#permissions">http://www.neurology.org/about/about_the_journal#permissions</a>
<b>Reprints</b>	Information about ordering reprints can be found online: <a href="http://n.neurology.org/subscribers/advertise">http://n.neurology.org/subscribers/advertise</a>

*Neurology*® is the official journal of the American Academy of Neurology. Published continuously since 1951, it is now a weekly with 48 issues per year. Copyright © 2023 American Academy of Neurology. All rights reserved. Print ISSN: 0028-3878. Online ISSN: 1526-632X.

