

Teaching NeuroImage: Plexus Neuritis After an Infection With the Tick-Borne Encephalitis Virus

Fanny Jende, MD, Tim Hilgenfeld, MD, Alexander Juerchott, MD, Felix Tobias Kurz, MD, PhD, Martin Bendszus, MD, Mircea Ariel Schoenfeld, MD, and Johann Malte Enno Jende, MD

Neurology® 2023;101:e677-e678. doi:10.1212/WNL.0000000000207328

Correspondence

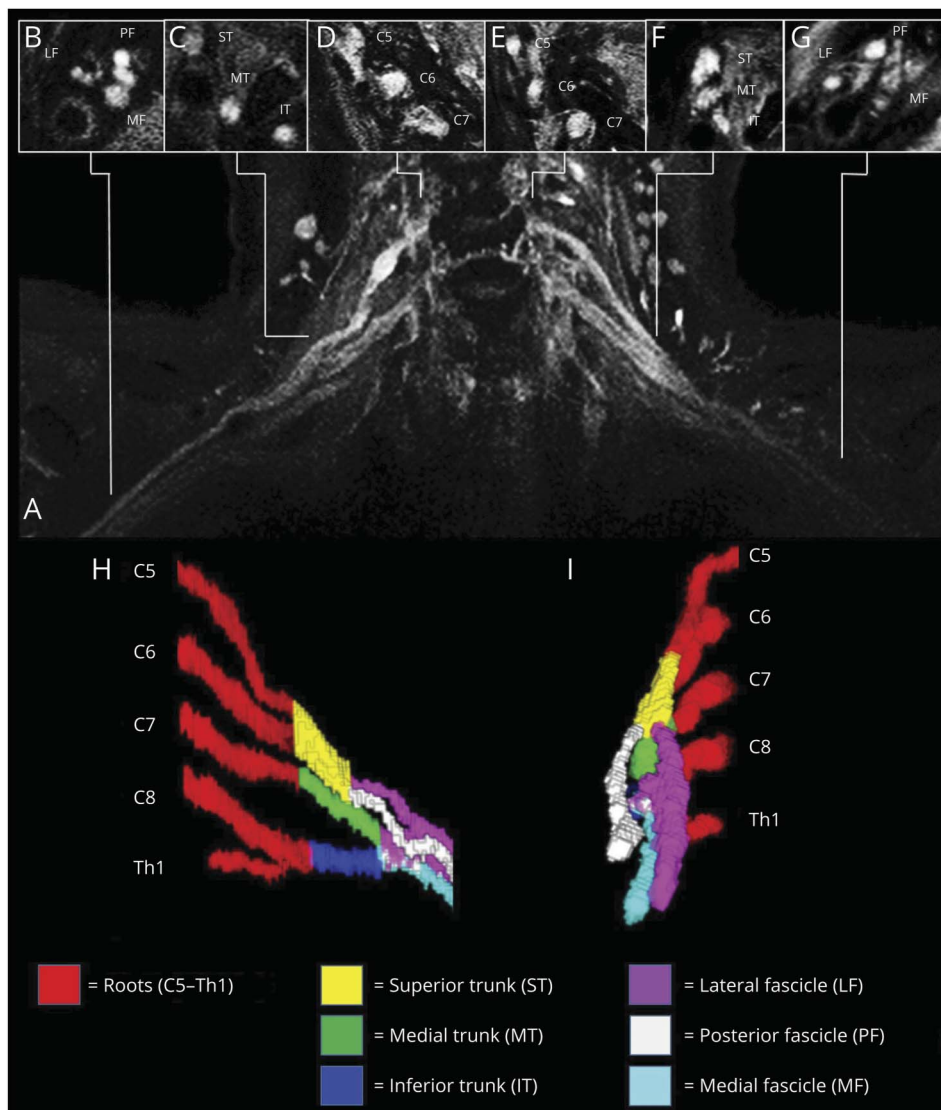
Dr. Jende
johann.jende@
med.uni-heidelberg.de

MORE ONLINE

Teaching slides

links.lww.com/WNL/C784

Figure MRI of the Brachial Plexus



(A) Coronal T2-weighted (T2w) fat-suppressed sequence (B) T2w-hyperintense lesions at the level of the fascicles (C) trunks, and (D) roots on the right and (E, F, G) left. (H) Three-dimensional reconstruction of the left brachial plexus in sagittal and (I) lateral views.

From the Kliniken Schmieder (F.J., M.A.S.), Clinic for Neurological Rehabilitation; Department of Neuroradiology (T.H., A.J., M.B., J.M.E.J.), Heidelberg University Hospital; and German Cancer Research Center (F.T.K.), Heidelberg, Germany.

Go to Neurology.org/N for full disclosures. Funding information and disclosures deemed relevant by the authors, if any, are provided at the end of the article.

A 71-year-old man presented with an impaired range of motion and pain in his left arm that had progressed for 8 days, accompanied by headaches and neck pain. He recalled a tick bite 1 month earlier. Clinical examination revealed a complete motor palsy of the left arm (0–1/5 in all muscles) and weakened reflexes of the upper and lower limbs (0–1/4). Electrophysiologic examinations showed signs of axonal damage to the radial, ulnar, and median nerves on the left. An MRI examination did not show any acute lesions of the meninges, brain, or spinal cord. The CSF showed lymphocytic pleocytosis and antibodies against tick-borne encephalitis virus (TBEV).¹ The CSF and blood samples were negative for borrelia. An MRI of the brachial plexus² showed bilateral inflammation of trunks and fascicles (Figure). The findings show that TBEV infection may cause plexitis after tick bites.

Author Contributions

F. Jende: drafting/revision of the article for content, including medical writing for content; major role in the acquisition of data; study concept or design; and analysis or interpretation of data. T. Hilgenfeld: major role in the acquisition of data. A. Juerchott: major role in the acquisition of data. F.T. Kurz: major role in the acquisition of data; analysis or interpretation of data. M. Bendszus: major role in the acquisition of data;

study concept or design. M.A. Schoenfeld: drafting/revision of the article for content, including medical writing for content; major role in the acquisition of data. J.M.E. Jende: drafting/revision of the article for content, including medical writing for content; major role in the acquisition of data; study concept or design; and analysis or interpretation of data.

Study Funding

No targeted funding reported.

Disclosure

The authors report no relevant disclosures. Go to [Neurology.org/N](https://www.neurology.org/N) for full disclosures.

Publication History

Received by *Neurology* October 26, 2022. Accepted in final form March 6, 2023. Submitted and externally peer reviewed. The handling editor was Resident and Fellow Section Editor Whitley Aamodt, MD, MPH.

References

1. Bogovic P, Strle F. Tick-borne encephalitis: a review of epidemiology, clinical characteristics, and management. *World J Clin Cases*. 2015;3(5):430-441.
2. Hilgenfeld T, Jende J, Schwarz D, et al. Somatotopic fascicular lesions of the brachial plexus demonstrated by high-resolution magnetic resonance neurography. *Investig Radiol*. 2017;52(12):741-746.

Neurology®

Teaching NeuroImage: Plexus Neuritis After an Infection With the Tick-Borne Encephalitis Virus

Fanny Jende, Tim Hilgenfeld, Alexander Juerchott, et al.
Neurology 2023;101:e677-e678 Published Online before print April 25, 2023
DOI 10.1212/WNL.0000000000207328

This information is current as of April 25, 2023

Updated Information & Services	including high resolution figures, can be found at: http://n.neurology.org/content/101/6/e677.full
References	This article cites 2 articles, 0 of which you can access for free at: http://n.neurology.org/content/101/6/e677.full#ref-list-1
Subspecialty Collections	This article, along with others on similar topics, appears in the following collection(s): Encephalitis http://n.neurology.org/cgi/collection/encephalitis Guillain-Barre syndrome http://n.neurology.org/cgi/collection/guillainbarre_syndrome Peripheral neuropathy http://n.neurology.org/cgi/collection/peripheral_neuropathy Viral infections http://n.neurology.org/cgi/collection/viral_infections
Permissions & Licensing	Information about reproducing this article in parts (figures, tables) or in its entirety can be found online at: http://www.neurology.org/about/about_the_journal#permissions
Reprints	Information about ordering reprints can be found online: http://n.neurology.org/subscribers/advertise

Neurology® is the official journal of the American Academy of Neurology. Published continuously since 1951, it is now a weekly with 48 issues per year. Copyright © 2023 American Academy of Neurology. All rights reserved. Print ISSN: 0028-3878. Online ISSN: 1526-632X.

