

Diagnostic Performance of Adding the Optic Nerve Region Assessed by Optical Coherence Tomography to the Diagnostic Criteria for Multiple Sclerosis

Gabriel Bsteh, PD, MD, PhD, Harald Hegen, MD PhD, Patrick Altmann, MD, PhD, Michael Auer, MD, PhD, Klaus Berek, MD, Franziska Di Pauli, MD, PhD, Barbara Kornek, MD, Nik Krajnc, MD, Fritz Leutmezer, MD, Stefan Macher, MD, PhD, Paulus Stefan Rommer, MD, Karin Zebenholzer, MD, Gudrun Zulehner, MD, Tobias Zrzavy, MD, PhD, Florian Deisenhammer, MD, Berthold Pemp, MD, and Thomas Berger, MD, MSc, for VMSD (Vienna Multiple Sclerosis Database) Group

Correspondence

Dr. Bsteh
gabriel.bsteh@
meduniwien.ac.at

Neurology® 2023;101:e784–e793. doi:10.1212/WNL.000000000207507

Abstract

Background and Objectives

The optic nerve has been recommended as an additional region for demonstrating dissemination in space (DIS) in diagnostic criteria for multiple sclerosis (MS). The aim of this study was to investigate whether adding the optic nerve region as determined by optical coherence tomography (OCT) as part of the DIS criteria improves the 2017 diagnostic criteria.

Methods

From a prospective observational study, we included patients with a first demyelinating event who had complete information to assess DIS and a spectral domain OCT scan obtained within 180 days. Modified DIS criteria (DIS + OCT) were constructed by adding the optic nerve to the current DIS regions based on validated thresholds for OCT intereye differences. Time to second clinical attack was the primary endpoint.

Results

We analyzed 267 patients with MS (mean age 31.3 years [SD 8.1], 69% female) during a median observation period of 59 months (range: 13–98). Adding the optic nerve as a fifth region improved the diagnostic performance by increasing accuracy (DIS + OCT 81.2% vs DIS 65.6%) and sensitivity (DIS + OCT 84.2% vs DIS 77.9%) without lowering specificity (DIS + OCT 52.2% vs DIS 52.2%). Fulfilling DIS + OCT criteria (≥ 2 of 5 DIS + OCT regions involved) indicated a similar risk of a second clinical attack (hazard ratio [HR] 3.6, CI 1.4–14.5) compared with a 2.5-fold increased risk when fulfilling DIS criteria (HR 2.5, CI 1.2–11.8). When the analysis was conducted according to topography of the first demyelinating event, DIS + OCT criteria performed similarly in both optic neuritis and nonoptic neuritis.

Discussion

Addition of the optic nerve, assessed by OCT, as a fifth region in the current DIS criteria improves diagnostic performance by increasing sensitivity without lowering specificity.

Classification of Evidence

This study provides Class II evidence that adding the optic nerve as determined by OCT as a fifth DIS criterion to the 2017 McDonald criteria improves diagnostic accuracy.

RELATED ARTICLE

Editorial

Is the Optic Nerve Overdue as a Criterion to Support the Diagnosis of Multiple Sclerosis?

Page 335

MORE ONLINE

Class of Evidence

Criteria for rating therapeutic and diagnostic studies

[NPublic.org/coe](https://npublic.org/coe)

From the Department of Neurology (G.B., P.A., B.K., N.K., F.L., S.M., P.S.R., K.Z., G.Z., T.Z., T.B.), Medical University of Vienna; Comprehensive Center for Clinical Neurosciences and Mental Health (G.B., P.A., B.K., N.K., F.L., S.M., P.S.R., K.Z., G.Z., T.Z., T.B.), Medical University of Vienna; Department of Neurology (H.H., M.A., K.B., F.D.P., F.D.), Medical University of Innsbruck; and Department of Ophthalmology (B.P.), Medical University of Vienna, Austria.

Go to Neurology.org/N for full disclosures. Funding information and disclosures deemed relevant by the authors, if any, are provided at the end of the article.

The Article Processing Charge was funded by the authors.

Vienna Multiple Sclerosis Database (VMSD) Group coinvestigators are listed in the appendix at the end of the article.

This is an open access article distributed under the terms of the Creative Commons Attribution-NonCommercial-NoDerivatives License 4.0 (CC BY-NC-ND), which permits downloading and sharing the work provided it is properly cited. The work cannot be changed in any way or used commercially without permission from the journal.

Glossary

ART = automatic real-time tracking; **AUC** = area under the curve; **CIS** = clinically isolated syndrome; **DIS** = dissemination in space; **DIT** = dissemination in time; **DMT** = disease-modifying treatments; **GCIPL** = ganglion cell and inner plexiform layer; **HR** = hazard ratio; **MS** = multiple sclerosis; **NPV** = negative predictive value; **OCB** = oligoclonal bands; **OCT** = optical coherence tomography; **ON** = optic neuritis; **PPV** = positive predictive value; **pRNFL** = peripapillary retinal nerve fiber layer; **VEP** = visual evoked potentials.

Diagnosis of multiple sclerosis (MS) requires proof of dissemination in space (DIS) and time (DIT).¹ While the presence of at least one clinical symptom typical of a CNS demyelinating lesion remains a prerequisite, diagnostic criteria for MS have evolved by using paraclinical investigations such as MRI and CSF analysis to provide a faster and more accurate diagnosis and, thus, enable earlier initiation of disease-modifying treatments (DMT).²⁻⁴ Optic neuritis (ON) is a typical manifestation of MS, constituting the initial symptom in about a quarter of cases.⁵ ON results in neuroaxonal damage to the optic nerve, measurable by optical coherence tomography (OCT) as reduced thickness of peripapillary retinal nerve fiber layer (pRNFL) and macular ganglion cell and inner plexiform layer (GCIPL).^{6,7} A further 10%–30% of patients with a clinically isolated syndrome (CIS) other than ON display signs of asymptomatic involvement of the optic nerve.^{5,8,9} There is now mounting evidence that interocular asymmetry in OCT provides highly sensitive, accurate, and reproducible detection of retinal atrophy as a result of MS-associated ON.^{7,10-18} Hence, OCT offers an intriguing method to objectify a history of clinical or subclinical optic nerve involvement in this context.¹⁹ In 2016, the Magnetic Resonance Imaging in MS (MAGNIMS) group recommended the inclusion of the optic nerve as an additional region for demonstrating DIS in McDonald criteria, established either clinically or paraclinically by MRI, OCT, or visual evoked potentials (VEP).^{5,8,9,20} However, evidence was deemed insufficient, and thus, the optic nerve was not incorporated into the 2017 version of the McDonald criteria.⁴ Since then, studies have evaluated the diagnostic performance of adding the optic nerve as a new region in DIS criteria using various combinations of clinical assessment, MRI, and VEP for determining optic nerve involvement.^{9,21,22} However, studies using OCT are currently lacking.

Here, we aimed to investigate the primary research question whether adding the optic nerve as determined by OCT as a fifth DIS criterion to the 2017 McDonald criteria improves diagnostic accuracy in a well-characterized cohort of patients with a first demyelinating event.

Methods

For this study, patients were retrospectively identified from an ongoing prospective observational cohort study of patients with a first demyelinating event recruited between 2014 and 2022 at the Departments of Neurology of the Medical Universities of Vienna and Innsbruck. In brief, baseline visit was conducted ≤ 180 days since occurrence of first clinical

symptom and comprised complete clinical diagnostic workup including cerebral and spinal cord MRI, OCT, and diagnostic lumbar puncture.

MRI scans were performed on 3T MR scanners. MRI protocols differed in some detail but included 3D fluid-attenuated inversion recovery sequences and T2 sequences. Each MRI scan was assessed by experienced neuroradiologists under routine conditions. IgG oligoclonal bands (OCB) were examined by standard isoelectric focusing with >2 bands considered OCB positive.²³ Follow-up visits were conducted at least biannually. Demographic data, neurologic history and status including Expanded Disability Status Scale, and treatment history including DMT were obtained from each participant at every visit.²⁴ Initiation of DMT was recommended to all patients. DMT status was classified as either initiation or no initiation of DMT after the first demyelinating event. Second clinical attack was defined as a second demyelinating event, occurring at least 30 days after the first demyelinating event.³

Optical Coherence Tomography

OCT was performed at baseline visit on both eyes. If the first demyelinating event was classified as ON by consensus of the treating neurologist and neuro-ophthalmologist, OCT was delayed until ≥ 90 days after onset of ON symptoms. OCT imaging was performed by experienced neuro-ophthalmologists using the same spectral domain OCT (Heidelberg Engineering, Heidelberg, Germany; Heidelberg eye explorer software version 6.9a) without pupil dilation in a dark room on both eyes of each patient. Measurement of pRNFL was performed by a 3.4-mm (12°) custom ring scan head (1536 A scans, automatic real-time tracking [ART]: 100 averaged frames) centered on the optic nerve. GCIPL thickness was measured by a macular volume scan ($20^\circ \times 20^\circ$, 512 A scans, 25 B scans, vertical alignment, ART: 16 averaged frames) centered on the macula. Mean GCIPL thickness of the 4 and outer quadrants of the circular grid around the foveola (corresponding to the 3 and 6 mm rings as defined by the Early Treatment Diabetic Retinopathy Study) was defined as GCIPL thickness.²⁵ Image processing was semiautomated using the built-in proprietary software for automated layer segmentation and manual correction of obvious errors. (O) obvious problems, (S) poor signal strength, (C) centration of scan, (A) algorithm failure, (R) retinal pathology other than MS relation, (I) illumination and (B) beam placement (OSCAR-IB) quality control criteria were applied for all examinations used and Advised Protocol for OCT Study Terminology and Elements (APOSTEL) criteria for reporting results.^{26,27} Patients with bilateral ON were excluded from the study. Other exclusion

criteria were presence of other neurologic comorbidities potentially affecting disability and diagnoses of ophthalmologic (i.e., myopia greater than -4 diopters, optic disc drusen, glaucoma), neurologic, or drug-related causes of retinal damage not attributable to MS.²⁶ Involvement of the optic nerve was defined as abnormal interocular asymmetry in retinal thickness in either GCIPL (cut-off value ≥ 4 μm) or pRNFL (cut-off value ≥ 5 μm).^{18,28} The investigators performing the OCT were blinded to clinical parameters and vice versa.

Design and Statistical Analyses

For the purpose of this study, the database was locked on August 1, 2022. To evaluate addition of the optic nerve as a fifth region to fulfill DIS, we included all patients aged 18 years or older and ≤ 180 days delay between onset of first clinical symptom and baseline visit who had complete information to assess the 5 DIS regions (MRI plus OCT) at baseline.

DIS and DIT were assessed at baseline according to 2017 McDonald criteria.⁴ Modified DIS criteria (DIS + OCT) were constructed by adding the optic nerve region (as defined by abnormal interocular asymmetry in OCT) as a fifth criterion to the 4 current regions (periventricular, cortical or juxtacortical, infratentorial, spinal cord) and using a cutoff value of ≥ 2 of 5. Occurrence of a second clinical attack was the primary endpoint.

Statistical analysis was performed using SPSS 26.0 (SPSS Inc, Chicago, IL). Categorical variables were expressed in frequencies and percentages. Continuous variables were tested for normal distribution by the Lilliefors test and, based on presence of normal distribution, expressed as either mean and SD or median and range.

Cox proportional hazards regression models regarding second clinical attack were performed using DIS and DIS + OCT as well as the number of DIS regions fulfilled as independent variables, adjusting for initiation of DMT after the first demyelinating event as a time-dependent variable.

Diagnostic performance of DIS + OCT in comparison with DIS, either alone or in combination with DIT, was analyzed by calculating area under the curve (AUC), sensitivity, specificity, positive predictive value (PPV), and negative predictive value (NPV) for second clinical attack.

DIT was defined based on MRI (simultaneous presence of gadolinium-enhancing and nonenhancing lesions on initial MRI or new T2-hyperintense or gadolinium-enhancing lesion on follow-up MRI) and/or OCB positivity.⁴ AUC was compared using variance estimates recovery on the basis of inverse hyperbolic sine transformations.²⁹ To mitigate distortion of results by late converters, these analyses were only conducted in a subgroup of the cohort with at least 5 years of follow-up.

Subgroup analyses for both Cox regression models and diagnostic performance analyses were conducted according to type of first demyelinating event (ON vs non-ON) to test

whether including the optic nerve by DIS + OCT would have different effects depending on the optic nerve involvement being symptomatic or asymptomatic.

Sensitivity analyses were conducted for effect of center as well by excluding patients with (1) treatment initiation before presenting a second clinical attack, (2) a follow-up of less than 2 years, and (3) a follow-up of less than 5 years. A 2-sided p value < 0.05 was considered statistically significant.

Standard Protocol Approvals, Registrations, and Patient Consents

The study was approved by the ethics committees of the Medical Universities of Vienna and Innsbruck (ethical approval number: 2323/2019 and AM3743-281/4). Written informed consent was obtained from all study participants.

Data Availability

Data supporting the findings of this study are available from the corresponding author on reasonable request by a qualified researcher and on approval by the ethics committee of the Medical University Vienna.

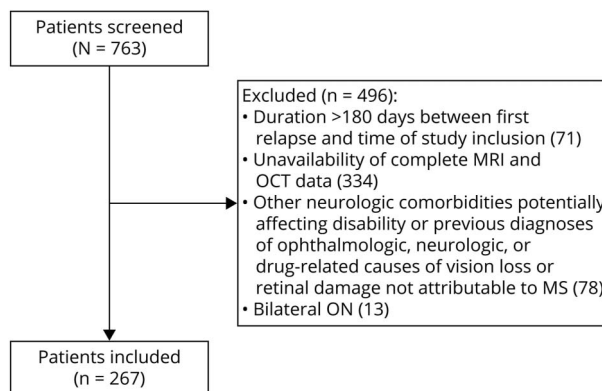
Results

Of 763 patients screened, 267 patients with MS were finally included with a median follow-up period of 59 months (range: 13–98). The detailed inclusion process is depicted in Figure 1.

Characteristics of the study cohort are given in Table 1. Of note, the screened cohort did not significantly differ from the final study cohort in any of the variables analyzed.

After a median 82 days (range: 2–180) from first demyelinating event to OCT scan, interocular asymmetry indicating optic nerve involvement was found in 96 (36.0%). Of 186 patients without ON at baseline, 28 (15.1%) had an

Figure 1 Flowchart of Study Inclusion/Exclusion Process



OCT = optical coherence tomography; ON = optic neuritis.

Table 1 Baseline Characteristics of the Study Cohort

	(n = 267)
Female patients ^a	184 (68.9)
Age at first demyelinating event ^b (y)	31.3 (8.1)
Type of first demyelinating event ^{a,d}	
ON ^a	81 (30.3)
Non-ON ^a	186 (69.7)
Pyramidal ^a	34 (12.7)
Cerebellar ^a	24 (9.0)
Brainstem ^a	23 (8.6)
Sensory ^a	122 (45.7)
Other ^a	4 (1.5)
EDSS at baseline ^c	2 (1–4.5)
MRI ^a	
Abnormal ^a	218 (81.6)
Contrast-enhancing lesions ^a	56 (21.0)
Positive OCB ^a	184 (68.9)
Duration from first symptoms to OCT ^b (d)	82 (2–180)
ON ^a	112 (90–180)
Non-ON ^a	63 (2–180)
Abnormal OCT (interocular asymmetry) ^a	107 (40.1)
ON ^a	79/81 (97.5)
Non-ON ^a	28/186 (15.1)
Duration of follow-up ^c (mo)	59 (13–98)

Abbreviations: EDSS = Expanded Disability Status Scale; MRI = magnetic resonance imaging; MS = multiple sclerosis; Non-ON = first demyelinating event other than ON; OCB = oligoclonal bands; OCT = optical coherence tomography; ON = optic neuritis.

^a Number (percentage).

^b Mean and SD.

^c Median and range.

^d Percentage exceeds 100% because of polysymptomatic first demyelinating event.

asymptomatic optic nerve involvement. A second clinical attack occurred in 100 patients (37.5%) after a mean 14.8 months (SD 18.5).

The risk of suffering a second clinical attack during follow-up increased with a growing number of DIS regions affected at baseline (Table 2). Referenced to patients with no region involved, the hazard ratio (HR) ranged from 5.9 (95% CI 1.7–18.3) in the group with one involved DIS region to 16.5 (CI 5.7–54.5) if all 5 DIS + OCT regions were involved. Patients in whom there was only involvement of the optic nerve still had a nearly 9-fold increased risk (HR 8.9; CI 2.0–25.2) of a second clinical attack. Fulfilling DIS criteria (≥ 2 of 4 DIS regions involved) translated to a 2.5-fold increased

risk of a second clinical attack (HR 2.5, CI 1.2–11.8) as compared with not fulfilling DIS, whereas fulfilling the modified DIS + OCT criteria (≥ 2 of 5 DIS + OCT regions involved) indicated a 3.6-fold risk increase (HR 3.6, CI 1.4–14.5) with reference to not fulfilling DIS + OCT criteria.

Of note, the confidence intervals display considerable overlap, and this study was not designed to formally compare prediction of second relapse between modified DIS + OCT and DIS. However, these analyses were performed to see whether the increase in sensitivity would have to be traded off against a lower risk of second relapse, which does not seem to be the case.

Comparing the subgroups of patients with ON and non-ON as the first demyelinating event (Table 3), DIS provided very similar risk estimates after ON and non-ON (HR 2.4 vs 2.6), while the modified DIS + OCT criteria seemed to indicate slightly higher risk in the ON than in non-ON group (HR 4.0 vs 2.6).

Of note, all risk estimates were adjusted for initiation of DMT after the first demyelinating event as a time-dependent variable. In addition, conducted sensitivity analyses did not indicate a significant impact of follow-up duration (neither for <2 years nor for <5 years) or study center on risk estimates (data not shown).

Diagnostic performance was assessed in the subgroup of patients with ≥ 5 years of follow-up (n = 118). Apart from a longer median observation period (71 vs 59 months in the whole cohort) and a higher proportion of second clinical attacks (95/118 patients [80.5%] vs 37.5% in the whole cohort), there were no significant differences in the diagnostic performance subgroup. OCT interocular asymmetry was abnormal in 46 (39.0%) with 15.5% of asymptomatic findings (13/84).

Diagnostic accuracy of modified DIS + OCT criteria for predicting a second clinical attack after the first demyelinating event was significantly higher than DIS criteria (AUC 81.2 vs 65.6, $p = 0.021$) by providing improved sensitivity (84.2% vs 77.9%) and NPV (44.4% vs 36.4%) without lowering specificity (52.2% vs 52.2%) and PPV (87.1% vs 87.9%) (Table 4). Taken together with DIT, modified DIS + OCT criteria still seemed slightly more accurate and more sensitive with equal specificity, although the differences were not statistically significant (Table 4).

Comparing diagnostic performance in ON vs non-ON as the first demyelinating event, modified DIS + OCT criteria displayed improved overall accuracy as well as improved sensitivity and NPV without hampering specificity compared with DIS criteria in both groups (Table 5). However, the improvement was more substantial in ON than in non-ON.

Again, there was no statistically significant difference between modified DIS + OCT criteria and DIS when adding fulfillment of DIT criteria, although DIS + OCT seemed slightly more accurate and more sensitive while maintaining specificity in both subgroups.

Table 2 Risk for a Second Clinical Attack According to Dissemination in Space

	Absolute number (%)	Second clinical attack (n, %)	Adjusted hazard ratio (95% CI)
No. of regions involved			
1	50 (18.7)	12/50 (24.0)	5.9 (1.7–18.3)
2	35 (13.1)	14/35 (40.0)	9.8 (2.4–33.1)
3	59 (22.1)	28/59 (47.5)	11.6 (3.8–35.3)
4	43 (16.1)	23/43 (53.5)	13.1 (4.0–38.2)
5	31 (11.6)	21/31 (67.7)	16.5 (5.7–54.5)
Only optic nerve involved	22 (8.2)	8/22 (36.4)	8.9 (2.0–25.2)
2017 DIS fulfilled ($\geq 2/4$)^a	147 (55.1)	75/147 (51.0)	2.5 (1.2–11.8) ^c
2017 DIS + OCT fulfilled ($\geq 2/5$)^b	168 (62.9)	86/168 (51.2)	3.6 (1.4–14.5) ^d

Abbreviations: DIS = dissemination in space; OCT = optical coherence tomography.

^a DIS criteria as defined in McDonald criteria 2017: at least 1 lesion in at least 2 of 4 regions (periventricular, cortical or juxtacortical, infratentorial, spinal cord).

^b Modified DIS criteria (DIS + OCT) were constructed by adding the optic nerve region (defined by abnormal interocular asymmetry in OCT): at least 1 lesion in at least 2 of 5 regions (periventricular, cortical or juxtacortical, infratentorial, spinal cord, optic nerve).

^c With reference to not fulfilling 2017 DIS criteria.

^d With reference to not fulfilling 2017 DIS + OCT criteria.

Sensitivity analyses did not show a significant impact of study center or DMT initiation before a second clinical attack on parameters of diagnostic accuracy (data not shown).

This study provides Class II evidence that adding the optic nerve as determined by OCT as a fifth DIS criterion to the 2017 McDonald criteria improves diagnostic accuracy.

Discussion

Investigating the effect of adding optic nerve involvement as determined by OCT as a fifth DIS criterion to current McDonald criteria in patients with a first demyelinating event, we found that the modified DIS + OCT criteria confer a

similar risk of developing a second demyelinating event and slightly improve diagnostic accuracy (81% vs 66%) by means of increasing sensitivity (84% vs 78%) without compromising specificity (52% vs 52%).

Our results are very much in line with a study using VEP instead of OCT to add the optic nerve to DIS criteria in an otherwise nearly identical setting, which reported similar risk increase for a second clinical attack and an improved diagnostic accuracy driven by increased sensitivity (82% vs 79%) without affecting specificity (52% vs 52%).²² An earlier study²¹ also reported increased sensitivity compared with the 2010 version of McDonald criteria (90% vs 87%) by adding the optic nerve by means of MRI and/or VEP, however, with the trade-off of decreased specificity (26% vs

Table 3 Risk for a Second Clinical Attack According to Dissemination in Space Criteria in Optic Neuritis vs Nonoptic Neuritis

	Absolute number (%)	Second clinical attack (n, %)	Adjusted hazard ratio (95% CI)
Optic neuritis (n = 81)			
2017 DIS fulfilled ($\geq 2/4$)^a	38 (46.9)	15/38 (39.5)	2.4 (1.1–11.5) ^c
2017 DIS + OCT fulfilled ($\geq 2/5$)^b	45 (55.6)	18/45 (40.0)	4.0 (1.5–16.2) ^d
Nonoptic neuritis (n = 186)			
2017 DIS fulfilled ($\geq 2/4$)^a	115 (61.8)	63/115 (54.8)	2.6 (1.3–12.3) ^c
2017 DIS + OCT fulfilled ($\geq 2/5$)^b	130 (69.9)	723/130 (55.4)	3.3 (1.4–13.8) ^d

Abbreviations: DIS = dissemination in space; OCT = optical coherence tomography.

^a DIS criteria as defined in McDonald criteria 2017: at least 1 lesion in at least 2 of 4 regions (periventricular, cortical or juxtacortical, infratentorial, spinal cord).

^b Modified DIS criteria (DIS + OCT) were constructed by adding the optic nerve region (defined by abnormal interocular asymmetry in OCT): at least 1 lesion in at least 2 of 5 regions (periventricular, cortical or juxtacortical, infratentorial, spinal cord, optic nerve).

^c With reference to not fulfilling 2017 DIS criteria.

^d With reference to not fulfilling 2017 DIS + OCT criteria.

Table 4 Diagnostic Performance of Dissemination in Space With and Without OCT for Second Clinical Attack at 5-Year Follow-up

	<u>Sensitivity</u>	<u>Specificity</u>	<u>PPV</u>	<u>NPV</u>	<u>Accuracy (AUC)</u>
	Percent (95% CI)	Percent (95% CI)	Percent (95% CI)	Percent (95% CI)	Percent (95% CI)
DIS 2017^a	77.9 (68.6–85.1)	52.2 (33.0–70.8)	87.1 (78.3–92.6)	36.4 (22.2–53.4)	65.6 (52.3–78.8)
DIS + OCT^b	84.2 (75.6–90.2)	52.2 (33.0–70.8)	87.9 (79.6–93.1)	44.4 (27.6–62.7)	81.2 (70.6–91.9)
DIS 2017 and DIT^{a,c}	75.8 (66.3–83.3)	69.6 (49.1–84.4)	91.1 (82.8–95.6)	41.0 (27.1–56.6)	72.7 (60.7–84.7)
DIS + OCT and DIT^{b,c}	76.8 (67.4–84.2)	69.6 (49.1–84.4)	91.3 (83.0–95.7)	42.1 (27.9–57.8)	73.2 (61.2–85.2)

Abbreviations: AUC = area under the curve; DIS = dissemination in space; DIT = dissemination in time; NPV = negative predictive value; OCT = optical coherence tomography; PPV = positive predictive value.

^a DIS criteria as defined in McDonald criteria 2017: at least 1 T2-hyperintense lesion in at least 2 of 4 regions (periventricular, cortical or juxtacortical, infratentorial, spinal cord).

^b Modified DIS criteria (DIS + OCT) were constructed by adding the optic nerve region (defined by abnormal interocular asymmetry in OCT): at least 1 lesion in at least 2 of 5 regions (periventricular, cortical or juxtacortical, infratentorial, spinal cord, optic nerve).

^c DIT criteria as defined in McDonald criteria 2017.

33%) resulting in similar diagnostic accuracy. The authors of a study,⁹ using a definition of symptomatic optic nerve involvement by means of clinical and/or VEP, also found increased sensitivity (95% vs 83%) at the expense of a decrease in specificity (57% vs 68%). In our study as well as in the VEP study,²² overall accuracy and sensitivity for a second clinical attack increased without a decrease in specificity. These differences could be explained by differences in baseline characteristics and/or varying follow-up periods influencing rates of second clinical attack and possibly by the different modalities/definitions used for establishing optic nerve involvement.

When adding DIT to DIS + OCT in our study, i.e., comparing current McDonald criteria with a version with optic nerve involvement defined by OCT intereye difference added as a fifth region for DIS, the difference between DIS + OCT + DIT and DIS 2017 + DIT was not statistically significant anymore, although DIS + OCT + DIT still seemed to display slightly better sensitivity and overall diagnostic accuracy for a second clinical attack than DIS 2017 + DIT. This is in line with studies using clinical, MRI, and VEP definitions of optic nerve involvement and is likely due to the available sample size because the improvement seems consistent through these studies in all subgroups.^{9,21,22}

Table 5 Diagnostic Performance in Optic Neuritis vs Nonoptic Neuritis of Dissemination in Space With and Without OCT for Second Clinical Attack at 5-Year Follow-up

	<u>Sensitivity</u>	<u>Specificity</u>	<u>PPV</u>	<u>NPV</u>	<u>Accuracy (AUC)</u>
	Percent (95% CI)	Percent (95% CI)	Percent (95% CI)	Percent (95% CI)	Percent (95% CI)
Optic neuritis					
DIS 2017^a	67.7 (50.1–81.4)	62.5 (30.6–86.3)	87.5 (69.0–95.7)	33.3 (15.2–58.3)	65.1 (43.3–87.0)
DIS + OCT^b	77.4 (60.2–88.6)	62.5 (30.6–86.3)	88.9 (71.9–96.2)	41.7 (19.3–68.1)	70.0 (48.3–91.6)
DIS 2017 and DIT^{a,c}	64.5 (47.0–78.9)	87.5 (52.9–99.4)	95.2 (77.3–99.8)	38.9 (20.3–61.4)	76.0 (58.5–93.5)
DIS + OCT and DIT^{a,c}	67.7 (50.1–81.4)	87.5 (52.9–99.4)	95.5 (78.2–99.8)	41.2 (21.6–64.0)	77.6 (60.5–94.8)
Nonoptic neuritis					
DIS 2017^a	84.4 (73.6–91.3)	53.3 (30.1–75.2)	88.5 (78.2–94.3)	44.4 (24.6–66.3)	68.9 (52.5–85.2)
DIS + OCT^b	85.9 (75.4–92.4)	53.3 (30.1–75.2)	88.7 (78.5–94.4)	47.1 (26.2–69.0)	69.6 (53.3–86.0)
DIS 2017 and DIT^{a,c}	76.6 (64.9–85.3)	60.0 (35.8–80.2)	89.1 (78.2–94.9)	37.5 (21.2–57.3)	68.3 (52.4–84.1)
DIS + OCT and DIT^{b,c}	78.1 (66.6–86.5)	60.0 (35.8–80.2)	89.3 (78.5–95.0)	39.1 (22.2–59.2)	69.1 (53.2–84.9)

Abbreviations: AUC = area under the curve; DIS = dissemination in space; DIT = dissemination in time; NPV = negative predictive value; OCT = optical coherence tomography; PPV = positive predictive value.

^a DIS criteria as defined in McDonald criteria 2017: at least 1 T2-hyperintense lesion in at least 2 of 4 regions (periventricular, cortical or juxtacortical, infratentorial, spinal cord).

^b Modified DIS criteria (DIS + OCT) were constructed by adding the optic nerve region (defined by abnormal interocular asymmetry in OCT): at least 1 lesion in at least 2 of 5 regions (periventricular, cortical or juxtacortical, infratentorial, spinal cord, optic nerve).

^c DIT criteria as defined in McDonald criteria 2017.

Looking into the potential impact of whether optic nerve involvement was symptomatic or asymptomatic, subgroup analyses revealed very similar results for both diagnostic performance and risk prediction with a slightly higher improvement in symptomatic optic nerve involvement (i.e., patients with ON as the first demyelinating event). This is also in line with reported results using VEP.²²

First, this underlines that OCT is able to accurately detect optic nerve involvement in both ON and non-ON CIS patients.^{18,28,30} In that context, it is important to point out that in symptomatic ON, OCT needs to be delayed ≥ 90 days after onset of ON symptoms to allow reliable detection of asymmetry by OCT.⁶ Second, our results further underscore that no distinction should be made between symptomatic and asymptomatic lesions when determining DIS.^{31,32} While the authors of a study reported that inclusion of the optic nerve only improved diagnostic performance in patients with symptomatic ON, this is most likely due to the fact that this study defined optic nerve involvement only clinically, which is less sensitive to detecting asymptomatic lesions compared with MRI, OCT, and VEP.^{9,30,33,34}

After the 2017 revision of the McDonald criteria did not include the optic nerve as a DIS region, we are convinced that the available overall body of evidence including our study is now sufficient to warrant that. Optic nerve involvement may be established either clinically, by imaging with MRI or OCT, or electrophysiologically by VEP.²⁰ Clinical assessment is based on detecting optic nerve atrophy or disc pallor but is technically challenging, requires availability of a trained neuro-ophthalmologist, and is less sensitive than paraclinical investigations.^{33,34} Thus, paraclinical investigations have been increasingly propagated in this context.

Retinal OCT provides a unique opportunity to depict the degree of clinical and even subclinical neuroaxonal damage in vivo with low expenditure and excellent reproducibility by means of measuring pRNFL and GCIPL thickness.^{7,35} Recent efforts by the scientific community have now yielded reliable and validated cutoffs for determining symptomatic and asymptomatic involvement of the optic nerve by OCT with high accuracy.^{18,28,36} OCT shows very good concordance with MRI detection of optic nerve involvement but has some considerable advantages over MRI because it is noninvasive, inexpensive, easy to perform and accessible, fast, and produces standardized, reliable quantitative measures.^{8,37} Thus, OCT represents an attractive option for determining involvement of the optic nerve.

We acknowledge several limitations to this study. Although data were derived from a prospective observational cohort study, the study outcomes and inclusion criteria for this study have been defined retrospectively, potentially introducing a selection bias compared with the full cohort. However, the full study cohort did not significantly differ from the final study cohort presented here in any of the variables analyzed. By only

selecting patients who had complete information (MRI plus OCT) to assess the 5 DIS regions at baseline, our cohort might have potentially been enriched. Application and timing of DMT might have influenced the results of our study. However, risk estimates of Cox regression models were adjusted for DMT as a time-dependent variable, and sensitivity analyses did not show a significant impact of DMT on diagnostic accuracy. OCT scans were conducted at 2 different centers creating the potential of confounding inter-rater variability. However, both centers used the same type of OCT device (Heidelberg Engineering) with the same software configurations and sensitivity analyses for effect of center did not indicate a significant effect of center. Our results are not directly applicable to other OCT devices, although previous findings suggest that retinal layer thickness thresholds might be robust independent of the OCT manufacturer. OCT scans were meticulously controlled for quality, and confounding factors were ruled out rigorously (e.g., severe myopia, optic disc drusen, diagnoses of ophthalmologic, neurologic, systemic or drug-related causes of retinal damage not attributable to MS), which limits applicability to populations excluded from this study. In this context, we emphasize that the study cohort almost exclusively consists of patients of Caucasian origin, limiting applicability to other ethnicities.

Using abnormal interocular asymmetry on OCT for determining involvement of the optic nerve is not applicable in bilateral ON, which was therefore excluded from the study.

While the concordance rate between GCIPL and pRNFL cutoff values was excellent (98.9%) in our cohort, likely because of the thorough quality control and ruling out of confounding influences, GCIPL is the more robust measure and should be preferred in clinical practice.^{17,28}

Generally, it needs to be stressed that abnormal interocular asymmetry on OCT is not specific for MS and may also occur because of other conditions such as ischemic or compressive optic neuropathy. Application of any version of McDonald criteria requires clinical presentation with a symptom typical of a demyelinating event and no better explanation for the clinical presentation (i.e., ruling out any relevant plausible alternative diagnosis).

Of note, patients who had only optic nerve involvement, i.e., with normal brain MRI, displayed a higher rate of second relapses than in other previously reported cohorts (36.4% vs 15%–20%).^{38,39} This is possibly due to the thorough definition of ON as well as a higher proportion of OCB positivity in our cohort, which might have led to a lower number of ON misdiagnoses and a higher rate of second relapses.

The constant evolution of diagnostic criteria for MS has yielded faster and more accurate diagnosis paving the way for earlier access to DMT for patients with MS.²⁻⁴ Still, there remains room for improvement. Clinically relevant, current McDonald

criteria put patients with ON as initial manifestation at a disadvantage. Because the optic nerve is not considered a DIS region, a symptomatic lesion of the optic nerve, although a typical initial manifestation of MS concerning a quarter of all patients, is less likely to lead to an MS diagnosis than a symptomatic lesion of the brainstem or the spinal cord.⁴⁰ As an illustrative example, a patient with a symptomatic spinal cord lesion and one contrast-enhancing periventricular lesion in brain MRI can be diagnosed with MS, whereas a patient with ON displaying abnormal interocular asymmetry on OCT and an MRI lesion in the optic nerve cannot be diagnosed with MS if the patient displays the identical contrast-enhancing periventricular lesion in brain MRI.

In conclusion, we show that addition of the optic nerve, assessed by OCT, as a fifth region in the current DIS criteria moderately improves diagnostic performance by increasing sensitivity without compromising specificity. This provides additional evidence arguing in favor of inclusion of the optic nerve in the upcoming revision of the McDonald criteria and, thus, establishing OCT within the spectrum of routine MS diagnostics.

Study Funding

The authors report no targeted funding.

Disclosure

G. Bsteh has participated in meetings sponsored by, received speaker honoraria from, or travel funding from Biogen, Celgene/BMS, Lilly, Merck, Novartis, Roche, Sanofi-Genzyme, and Teva and received honoraria for consulting Biogen, Celgene/BMS, Novartis, Roche, Sanofi-Genzyme, and Teva. He has received unrestricted research grants from Celgene/BMS and Novartis. H. Hegen has participated in meetings sponsored by, received speaker honoraria from, or travel funding from Bayer, Biogen, Celgene, Merck, Novartis, Sanofi-Genzyme, Siemens, and Teva and received honoraria for consulting Biogen, Celgene, Novartis, and Teva. P. Altmann has participated in meetings sponsored by, received speaker honoraria from, or travel funding from Biogen, Merck, Roche, Sanofi-Genzyme, and Teva and received honoraria for consulting from Biogen. He received a research grant from Quanterix International and was awarded a combined sponsorship from Biogen, Merck, Sanofi-Genzyme, Roche, and Teva for a clinical study. M. Auer received speaker honoraria and/or travel grants from Biogen, Merck, Novartis, and Sanofi-Genzyme. K. Berek has participated in meetings sponsored by and received travel funding from Biogen, Roche, Sanofi-Genzyme, and Teva. F. Di Pauli has participated in meetings sponsored by, received honoraria from (lectures, advisory boards, consultations), or travel funding from Biogen, Celgene BMS, Horizon, Johnson&Johnson, Merck, Novartis, Sanofi-Genzyme, Teva, and Roche. Her institution has received research grants from Roche. B. Kornek has

received honoraria for speaking and for consulting from Biogen, BMS-Celgene, Johnson&Johnson, Merck, Novartis, Roche, Teva, and Sanofi-Genzyme outside of the submitted work. No conflict of interest with respect to the present study. N. Krajnc has participated in meetings sponsored by, received speaker honoraria from, or travel funding from BMS/Celgene, Janssen-Cilag, Merck, Novartis, Roche, and Sanofi-Genzyme and held a grant for a Multiple Sclerosis Clinical Training Fellowship Programme from the European Committee for Treatment and Research in Multiple Sclerosis (ECTRIMS). F. Leutmezer has participated in meetings sponsored by, received speaker honoraria from, or travel funding from Actelion, Almirall, Biogen, Celgene, Johnson&Johnson, MedDay, Merck, Novartis, Roche, Sanofi-Genzyme, and Teva and received honoraria for consulting Biogen, Celgene, Merck, Novartis, Roche, Sanofi-Genzyme, and Teva. S. Macher declares no conflict of interest relevant to this study. P. Rommer has received honoraria for consultancy/speaking from AbbVie, Allmiral, Alexion, Biogen, Merck, Novartis, Roche, Sandoz, Sanofi-Genzyme and has received research grants from Amicus, Biogen, Merck, Roche. K. Zebenholzer received speaking honoraria or travel grants from Biogen, Novartis, and Sanofi-Genzyme. G. Zulehner has participated in meetings sponsored by or received travel funding from Biogen, Merck, Novartis, Roche, Sanofi-Genzyme, and Teva. T. Zrzavy has participated in meetings sponsored by or received travel funding from Biogen, Merck, Novartis, Roche, Sanofi-Genzyme, and Teva. F. Deisenhammer has participated in meetings sponsored by or received honoraria for acting as an advisor/speaker for Alexion, Almirall, Biogen, Celgene, Merck, Novartis, Roche, and Sanofi-Genzyme. His institution received scientific grants from Biogen and Sanofi-Genzyme. B. Pemp has received honoraria for consulting from Novartis, has received honoraria for advisory boards/consulting from Chiesi and GenSight, and has received speaker honoraria from Chiesi and Santen. T. Berger has participated in meetings sponsored by and received honoraria (lectures, advisory boards, consultations) from pharmaceutical companies marketing treatments for MS: Allergan, Bayer, Biogen, Bionorica, BMS/Celgene, Genesis, GSK, GW/Jazz Pharma, Horizon, Janssen-Cilag, MedDay, Merck, Novartis, Octapharma, Roche, Sandoz, Sanofi-Genzyme, Teva, and UCB. His institution has received financial support in the past 12 months by unrestricted research grants (Biogen, Bayer, BMS/Celgene, Merck, Novartis, Roche, Sanofi-Genzyme, and Teva) and for participation in clinical trials in multiple sclerosis sponsored by Alexion, Bayer, Biogen, Merck, Novartis, Octapharma, Roche, Sanofi-Genzyme, and Teva). Go to [Neurology.org/N](https://www.neurology.org/N) for full disclosures.

Publication History

Received by *Neurology* November 2, 2022. Accepted in final form April 24, 2023. Submitted and externally peer reviewed. The handling editor was Deputy Editor Olga Ciccarelli, MD, PhD, FRCP.

Appendix 1 Authors

Name	Location	Contribution
Gabriel Bsteh, PD, MD, PhD	Department of Neurology, Medical University of Vienna, Vienna, Austria	Study concept and design, patient recruitment, acquisition of data, statistical analysis and interpretation of data, drafting of manuscript, study supervision
Harald Hegen, MD, PhD	Department of Neurology, Medical University of Innsbruck, Innsbruck, Austria	Patient recruitment, acquisition of data, assisted in statistical analysis, interpretation of data, critical revision of manuscript for intellectual content
Patrick Altmann, MD, PhD	Department of Neurology, Medical University of Vienna, Vienna, Austria	Patient recruitment, acquisition of data, critical revision of manuscript for intellectual content.
Michael Auer, MD, PhD	Department of Neurology, Medical University of Innsbruck, Innsbruck, Austria	Patient recruitment, acquisition of data, critical revision of manuscript for intellectual content
Klaus Berek, MD	Department of Neurology, Medical University of Innsbruck, Innsbruck, Austria	Patient recruitment, acquisition of data, critical revision of manuscript for intellectual content
Franziska Di Pauli, MD, PhD	Department of Neurology, Medical University of Innsbruck, Innsbruck, Austria	Patient recruitment, acquisition of data, critical revision of manuscript for intellectual content
Barbara Kornek, MD	Department of Neurology, Medical University of Vienna, Vienna, Austria	Patient recruitment, acquisition of data, critical revision of manuscript for intellectual content
Nik Krajnc, MD	Department of Neurology, Medical University of Vienna, Vienna, Austria	Patient recruitment, acquisition of data, interpretation of data, critical revision of manuscript for intellectual content
Fritz Leutmezer, MD	Department of Neurology, Medical University of Vienna, Vienna, Austria	Patient recruitment, acquisition of data, critical revision of manuscript for intellectual content
Stefan Macher, MD, PhD	Department of Neurology, Medical University of Vienna, Vienna, Austria	Patient recruitment, acquisition of data, critical revision of manuscript for intellectual content
Paulus Stefan Rommer, MD	Department of Neurology, Medical University of Vienna, Vienna, Austria	Patient recruitment, acquisition of data, critical revision of manuscript for intellectual content
Karin Zebenholzer, Prof, MD	Department of Neurology, Medical University of Vienna, Vienna, Austria	Patient recruitment, acquisition of data, critical revision of manuscript for intellectual content
Gudrun Zulehner, MD	Department of Neurology, Medical University of Vienna, Vienna, Austria	Patient recruitment, acquisition of data, critical revision of manuscript for intellectual content.
Tobias Zrzavy, MD, PhD	Department of Neurology, Medical University of Vienna, Vienna, Austria	Patient recruitment, acquisition of data, critical revision of manuscript for intellectual content

Appendix 1 (continued)

Name	Location	Contribution
Florian Deisenhammer, MD	Department of Neurology, Medical University of Innsbruck, Innsbruck, Austria	Patient recruitment, acquisition of data, critical revision of manuscript for intellectual content
Berthold Pemp, MD	Department of Ophthalmology, Medical University of Vienna, Vienna, Austria	Patient recruitment, acquisition of data, critical revision of manuscript for intellectual content
Thomas Berger, MD, MSc	Department of Neurology, Medical University of Vienna, Vienna, Austria	Study concept and design, patient recruitment, interpretation of data, critical revision of manuscript for intellectual content

Appendix 2 Coinvestigators

Name	Location	Role	Contribution
Monschein, Tobias, MD	Department of Neurology, Medical University of Vienna, Vienna, Austria	Site Investigator	Acquisition of data
Rinner, Walter, Prof MD	Department of Neurology, Medical University of Vienna, Vienna, Austria	Site Investigator	Acquisition of data
Schmied, Christiane, Prof MD	Department of Neurology, Medical University of Vienna, Vienna, Austria	Site Investigator	Acquisition of data

References

- Compston A, Coles A. Multiple sclerosis. *Lancet*. 2002;359(9313):1221-1231. doi: 10.1016/s0140-6736(02)08220-x
- Polman CH, Reingold SC, Edan G, et al. Diagnostic criteria for multiple sclerosis: 2005 revisions to the "McDonald Criteria". *Ann Neurol*. 2005;58(6):840-846. doi: 10.1002/ana.20703
- Polman CH, Reingold SC, Banwell B, et al. Diagnostic criteria for multiple sclerosis: 2010 revisions to the McDonald criteria. *Ann Neurol*. 2011;69(2):292-302. doi: 10.1002/ana.22366
- Thompson AJ, Banwell BL, Barkhof F, et al. Diagnosis of multiple sclerosis: 2017 revisions of the McDonald criteria. *Lancet Neurol*. 2018;17(2):162-173. doi: 10.1016/s1474-4422(17)30470-2
- Toosy AT, Mason DF, Miller DH. Optic neuritis. *Lancet Neurol*. 2014;13(1):83-99. doi: 10.1016/s1474-4422(13)70259-x
- Gabilondo I, Martinez-Lapiscina EH, Fraga-Pumar E, et al. Dynamics of retinal injury after acute optic neuritis. *Ann Neurol*. 2015;77(3):517-528. doi: 10.1002/ana.24351
- Petzold A, Balcer LJ, Calabresi PA, et al. Retinal layer segmentation in multiple sclerosis: a systematic review and meta-analysis. *Lancet Neurol*. 2017;16(10):797-812. doi: 10.1016/s1474-4422(17)30278-8
- London F, Zéphir H, Drumez E, et al. Optical coherence tomography: a window to the optic nerve in clinically isolated syndrome. *Brain*. 2019;142(4):903-915. doi: 10.1093/brain/awz038
- Brownlee WJ, Miszkiel KA, Tur C, Barkhof F, Miller DH, Ciccarelli O. Inclusion of optic nerve involvement in dissemination in space criteria for multiple sclerosis. *Neurology*. 2018;91(12):e1130-e1134. doi: 10.1212/wnl.00000000000006207
- Petzold A, de Boer JF, Schippling S, et al. Optical coherence tomography in multiple sclerosis: a systematic review and meta-analysis. *Lancet Neurol*. 2010;9:921-932. doi: 10.1016/s1474-4422(10)70168-x
- Behbehani R, Ali A, Al-Omairah H, Rousseff RT. Optimization of spectral domain optical coherence tomography and visual evoked potentials to identify unilateral optic neuritis. *Mult Scler Relat Dis*. 2020;41:101988. doi: 10.1016/j.msard.2020.101988
- Davion JB, Lopes R, Drumez E, et al. Asymptomatic optic nerve lesions: an underestimated cause of silent retinal atrophy in MS. *Neurology*. 2020;94(23):e2468-e2478. doi: 10.1212/WNL.00000000000009504

13. Outteryck O, Lopes R, Drumez É, et al. Optical coherence tomography for detection of asymptomatic optic nerve lesions in clinically isolated syndrome. *Neurology*. 2020; 95(6):e733-e744. doi. 10.1212/wnl.00000000000009832
14. Villoslada P, Sanchez-Dalmau B, Galetta S. Optical coherence tomography: a useful tool for identifying subclinical optic neuropathy in diagnosing multiple sclerosis. *Neurology*. 2020;95(6):239-240. doi. 10.1212/wnl.0000000000009840
15. Coric D, Balk LJ, Uitdehaag BMJ, Petzold A. Diagnostic accuracy of optical coherence tomography inter-eye percentage difference for optic neuritis in multiple sclerosis. *Eur J Neurol*. 2017;24(12):1479-1484. doi. 10.1111/ene.13443
16. Nolan RC, Galetta SL, Frohman TC, et al. Optimal intereye difference thresholds in retinal nerve fiber layer thickness for predicting a unilateral optic nerve lesion in multiple sclerosis. *J Neuroophthalmol*. 2018;38(4):451-458. doi. 10.1097/wno.0000000000000629
17. Bijvank JN, Uitdehaag BMJ, Petzold A. Retinal inter-eye difference and atrophy progression in multiple sclerosis diagnostics. *J Neurol Neurosurg Psychiatry*. 2021; 93(2):216-219. doi. 10.1136/jnnp-2021-327468
18. Bsteh G, Hegen H, Altmann P, et al. Validation of inter-eye difference thresholds in optical coherence tomography for identification of optic neuritis in multiple sclerosis. *Mult Scler Relat Dis*. 2020;45:102403. doi. 10.1016/j.msard.2020.102403
19. Costello F, Burton JM. Retinal imaging with optical coherence tomography: a biomarker in multiple sclerosis? *Eye Brain*. 2018;10:47-63. doi. 10.2147/eb.s139417
20. Filippi M, Rocca MA, Ciccarelli O, et al. MRI criteria for the diagnosis of multiple sclerosis: MAGNIMS consensus guidelines. *Lancet Neurol*. 2016;15(3):292-303. doi. 10.1016/s1474-4422(15)00393-2
21. Filippi M, Preziosa P, Meani A, et al. Prediction of a multiple sclerosis diagnosis in patients with clinically isolated syndrome using the 2016 MAGNIMS and 2010 McDonald criteria: a retrospective study. *Lancet Neurol*. 2018;17(2):133-142. doi. 10.1016/s1474-4422(17)30469-6
22. Vidal-Jordana A, Rovira A, Arrambide G, et al. Optic nerve topography in multiple sclerosis diagnosis: the utility of visual evoked potentials. *Neurology*. 2021;96(4): e482-e490. doi. 10.1212/wnl.0000000000011339
23. Freedman MS, Thompson EJ, Deisenhammer F, et al. Recommended standard of cerebrospinal fluid analysis in the diagnosis of multiple sclerosis: a consensus statement. *Arch Neurol*. 2005;62(6):865-870. doi. 10.1001/archneur.62.6.865
24. Kurtzke JF. Rating neurologic impairment in multiple sclerosis: an expanded disability status scale (EDSS). *Neurology*. 1983;33(11):1444-1452. doi. 10.1212/wnl.33.11.1444
25. Photocoagulation for diabetic macular edema. Early treatment diabetic Retinopathy study report number 1. Early Treatment Diabetic Retinopathy Study research group. *Arch Ophthalmol*. 1985;103:1796.
26. Schippling S, Balk L, Costello F, et al. Quality control for retinal OCT in multiple sclerosis: validation of the OSCAR-IB criteria. *Mult Scler J*. 2014;21(2):163-170. doi. 10.1177/1352458514538110
27. Cruz-Herranz A, Balk LJ, Oberwahrenbrock T, et al. The APOSTEL recommendations for reporting quantitative optical coherence tomography studies. *Neurology*. 2016;86(24):2303-2309. doi. 10.1212/wnl.0000000000002774
28. Nolan-Kenney RC, Liu M, Akhand O, et al. Optimal intereye difference thresholds by optical coherence tomography in multiple sclerosis: an international study. *Ann Neurol*. 2019;85(5):618-629. doi. 10.1002/ana.25462
29. Zou GY, Yue L. Using confidence intervals to compare several correlated areas under the receiver operating characteristic curves. *Stat Med*. 2013;32(29):5077-5090. doi. 10.1002/sim.5889
30. Leocani L, Guerrieri S, Comi G. Visual evoked potentials as a biomarker in multiple sclerosis and associated optic neuritis. *J Neuro Ophthalmol*. 2018;38(3):350-357. doi. 10.1097/wno.0000000000000704
31. Tintore M, Otero-Romero S, Rio J, et al. Contribution of the symptomatic lesion in establishing MS diagnosis and prognosis. *Neurology*. 2016;87(13):1368-1374. doi. 10.1212/wnl.0000000000003144
32. Brownlee WJ, Swanton JK, Miszkiel KA, Miller DH, Ciccarelli O. Should the symptomatic region be included in dissemination in space in MRI criteria for MS? *Neurology*. 2016;87(7):680-683. doi. 10.1212/wnl.0000000000002975
33. Sisto D, Trojano M, Vetrugno M, Trabucco T, Iliceto G, Sborgia C. Subclinical visual involvement in multiple sclerosis: a study by MRI, VEPs, frequency-doubling perimetry, standard perimetry, and contrast sensitivity. *Invest Ophthalm Vis Sci*. 2005;46(4): 1264-1268. doi. 10.1167/iovs.03-1213
34. Yuksel B, Dogan B, Koctekin B, et al. Color vision testing versus pattern visual evoked potentials and optical coherence tomography parameters in subclinical optic nerve involvement in multiple sclerosis. *J Clin Neurosci*. 2019;61:48-53. doi. 10.1016/j.jocn.2018.11.011
35. Pemp B, Kardon RH, Kircher K, Pernicka E, Schmidt-Erfurth U, Reitner A. Effectiveness of averaging strategies to reduce variance in retinal nerve fibre layer thickness measurements using spectral-domain optical coherence tomography. *Graefes Arch Clin Exp Ophthalmol*. 2013;251(7):1841-1848. doi: 10.1007/s00417-013-2337-0
36. Xu SC, Kardon RH, Leavitt JA, Flanagan EP, Pittock SJ, Chen JJ. Optical coherence tomography is highly sensitive in detecting prior optic neuritis. *Neurology*. 2019; 92(6):e527-e535. doi. 10.1212/wnl.0000000000006873
37. Ontaneda D, Fox RJ. Imaging as an outcome measure in multiple sclerosis. *Neurotherapeutics*. 2017;14:24-34. doi. 10.1007/s13311-016-0479-6
38. Tintore M, Rovira A, Rio J, et al. Defining high, medium and low impact prognostic factors for developing multiple sclerosis. *Brain*. 2015;138(7):1863-1874. doi. 10.1093/brain/awv105
39. Fisniku LK, Brex PA, Altmann DR, et al. Disability and T2 MRI lesions: a 20-year follow-up of patients with relapse onset of multiple sclerosis. *Brain*. 2008;131(3): 808-817. doi. 10.1093/brain/awm329
40. Galetta SL, Balcer LJ. The optic nerve should be included as one of the typical CNS regions for establishing dissemination in space when diagnosing MS—yes. *Mult Scler J*. 2018;24(2):121-122. doi. 10.1177/1352458517721054

Neurology®

Diagnostic Performance of Adding the Optic Nerve Region Assessed by Optical Coherence Tomography to the Diagnostic Criteria for Multiple Sclerosis

Gabriel Bsteh, Harald Hegen, Patrick Altmann, et al.

Neurology 2023;101:e784-e793 Published Online before print July 3, 2023

DOI 10.1212/WNL.0000000000207507

This information is current as of July 3, 2023

Updated Information & Services	including high resolution figures, can be found at: http://n.neurology.org/content/101/8/e784.full
References	This article cites 40 articles, 10 of which you can access for free at: http://n.neurology.org/content/101/8/e784.full#ref-list-1
Subspecialty Collections	This article, along with others on similar topics, appears in the following collection(s): Class II http://n.neurology.org/cgi/collection/class_ii Multiple sclerosis http://n.neurology.org/cgi/collection/multiple_sclerosis Optic nerve http://n.neurology.org/cgi/collection/optic_nerve
Permissions & Licensing	Information about reproducing this article in parts (figures, tables) or in its entirety can be found online at: http://www.neurology.org/about/about_the_journal#permissions
Reprints	Information about ordering reprints can be found online: http://n.neurology.org/subscribers/advertise

Neurology® is the official journal of the American Academy of Neurology. Published continuously since 1951, it is now a weekly with 48 issues per year. Copyright © 2023 The Author(s). Published by Wolters Kluwer Health, Inc. on behalf of the American Academy of Neurology. All rights reserved. Print ISSN: 0028-3878. Online ISSN: 1526-632X.

