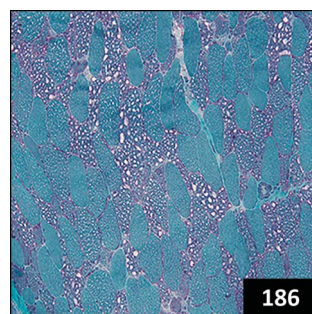
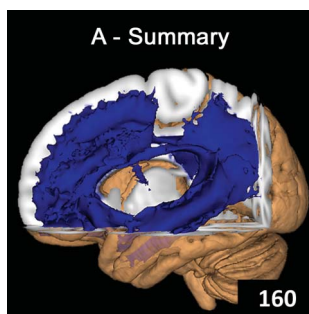
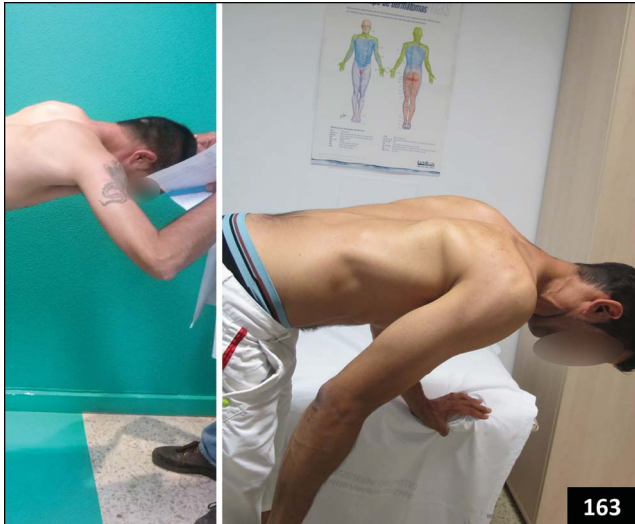Select figures listed on the Table of Contents only appear within the full-length articles online.

In Focus

- 151 **Spotlight on the July 24 issue**
- 152 **This Week's *Neurology*® Podcast**

Editorials

- 153 **Not all, but specific types of cognitive complaints predict decline to MCI**
F. Jessen and F.S. Rodriguez (née Then)
- 155 **Amended diagnostic protocol increases the early diagnosis of sporadic Creutzfeldt-Jakob disease**
A. Bizzi and K. Peoc'h
- 157 **Spinal cord atrophy rates: Ready for prime time in multiple sclerosis clinical trials?**
F. Prados and F. Barkhof

Articles: Short Format

Full articles at Neurology.org/N

- 159 **Subjective cognitive decline and risk of MCI: The Mayo Clinic Study of Aging**
A.C. van Harten, M.M. Mielke, D.M. Swenson-Dravis, C.E. Hagen, K.K. Edwards, R.O. Roberts, Y.E. Geda, D.S. Knopman, and R.C. Petersen
👉 Editorial, p. 153
- 160 **Loss of white matter integrity reflects tau accumulation in Alzheimer disease defined regions**
J.F. Strain, R.X. Smith, H. Beaumont, C.M. Roe, B.A. Gordon, S. Mishra, B. Adeyemo, J.J. Christensen, Y. Su, J.C. Morris, T.L.S. Benzinger, and B.M. Ances
- 161 **Biallelic *SQSTM1* mutations in early-onset, variably progressive neurodegeneration**
V. Muto, E. Flex, Z. Kupchinsky, G. Primiano, H. Galehdari, M. Dehghani, S. Cecchetti, G. Carpentieri, T. Rizza, N. Mazaheri, A. Sedaghat, M.Y. Vahidi Mehrjardi, A. Traversa, M. Di Nottia, M.M. Kousi, Y. Jamshidi, A. Cioffi, V. Caputo, R.A. Malamiri, F. Pantaleoni, S. Martinelli, A.R. Jeffries, J. Zeighami, A. Sherafat, D. Di Giuda, G.R. Shariati, R. Carrozzo, N. Katsanis, R. Maroofian, S. Servidei, and M. Tartaglia
👉 Video
- 162 **Validation and utilization of amended diagnostic criteria in Creutzfeldt-Jakob disease surveillance**
P. Hermann, M. Laux, M. Glatzel, J. Matschke, T. Knipper, S. Goebel, J. Treig, W. Schulz-Schaeffer, M. Cramm, M. Schmitz, and I. Zerr
👉 Editorial, p. 155 👉 Class of Evidence
- 163 **A Roma founder *BINI* mutation causes a novel phenotype of centronuclear myopathy with rigid spine**
M. Cabrera-Serrano, F. Mavillard, V. Biancalana, E. Rivas, B. Morar, A. Hernández-Láin, M. Olive, N. Muelas, E. Khan, A. Carvajal, P. Quiroga, J. Díaz-Manera, M. Davis, R. Avila, C. Domínguez, N.B. Romero, J.J. Vílchez, D. Comas, N.G. Laing, J. Laporte, L. Kalaydjieva, and C. Paradas
- 164 **Spinal cord volume loss: A marker of disease progression in multiple sclerosis**
C. Tsagkas, S. Magon, L. Gaetano, S. Pezold, Y. Naegelin, M. Amann, C. Stippich, P. Cattin, J. Wuerfel, O. Bieri, T. Sprenger, L. Kappos, and K. Parmar
👉 Editorial, p. 157
- 165 **Drug reaction with eosinophilia and systemic symptoms after daclizumab therapy**
S. Rauer, L. Stork, H. Urbach, A. Stathi, A. Marx, P. Süß, M. Prinz, W. Brück, and I. Metz
- 166 **Noninvasive vagus nerve stimulation as acute therapy for migraine: The randomized PRESTO study**
C. Tassorelli, L. Grazi, M. de Tommaso, G. Pierangeli, P. Martelletti, I. Rainero, S. Dorlas, P. Geppetti, A. Ambrosini, P. Sarchielli, E. Liebler, and P. Barbanti, On behalf of the PRESTO Study Group
👉 CME Course 👉 Open Access Article 👉 Podcast
👉 Class of Evidence

👉 Ahead of Print Articles and Editorials

NPub.org/aheadofprint

Continued

- 167 **Comment: Noninvasive neurostimulation for migraine should be part of the general neurologist's therapeutic armamentarium**
R.B. Lipton and P.J. Goadsby
- 168 **Female sex hormones in men with migraine**
W.P.J. van Oosterhout, G.G. Schoonman, E.W. van Zwet, O.M. Dekkers, G.M. Terwindt, A. MaassenVanDenBrink, and M.D. Ferrari
- 169 **Urinary cadmium concentration and the risk of ischemic stroke**
C. Chen, P. Xun, C. Tsinovoi, L.A. McClure, J. Brockman, L. MacDonald, M. Cushman, J. Cai, L. Kamendulis, J. Mackey, and K. He
[CME Course](#)

What's Happening

- 170 **What's happening in *Neurology*[®]**
- 171 **What's happening in *Neurology*[®] *Clinical Practice***
- 172 **What's happening in *Neurology*[®] *Genetics***
- 173 **What's happening in *Neurology*[®] *Neuroimmunology & Neuroinflammation***
- 174 **What's happening in *Without Borders***

Historical Neurology

- 175 **Denise Louis-Bar: The eponymous woman of Louis-Bar syndrome**
E.A. Coon, P.J. Koehler, and C.J. Boes

Clinical/Scientific Notes

- 180 **IgLONS: A case with predominant cerebellar tau deposits and leptomenigeal inflammation**
F. Schöberl, J. Levin, J. Remi, N. Goldschagg, O. Eren, N. Okamura, M. Unterrainer, A. Rominger, N. Albert, and M. Brendel

Reflections: Neurology and the Humanities

- 183 **An unambiguous prognosis**
L.K. Ronan
[Audio](#)

NeuroImages

- 185 **Gold thread acupuncture for hemifacial spasm**
S. Kwon and G. Kim

Resident & Fellow Section

- 187 **Pearls & Oysters: A curable myopathy manifesting as exercise intolerance and respiratory failure**
A.M.S. Silva, R.H. Mendonça, D.C. Soares, D. Callegaro, V.M. Caldas, I.N. Perissinotti, M.S. Carvalho, and E. Zanoteli
- e392 **Clinical Reasoning: A patient with multiple cranial nerve palsies and areflexic paraparesis**
R.K. Garg, I. Rizvi, H.S. Malhotra, M.M. Mehta, M. Jain, M.M. Goel, R. Uniyal, and N. Kumar

- e396 **Teaching NeuroImages: Alexander disease with features of both frontal and bulbospinal involvement**

T.-S. Nam, K.-W. Kang, S.-Y. Choi, and M.-K. Kim

- e398 **The frontal eye field**

P. Bourdillon, M. Guénot, P.-A. Beuriat, and K. Ostrowsky-Coste


[Video](#)

Disputes & Debates: Editors' Choice

- 191 **Editors' note: Teaching NeuroImages: A rare case of giant perivascular spaces in the midbrain manifesting as atypical parkinsonism**
M. Alcauskas and S. Galetta
- 191 **Reader response: Teaching NeuroImages: A rare case of giant perivascular spaces in the midbrain manifesting as atypical parkinsonism**
S. Bhattacharjee
- 192 **Author response: Teaching NeuroImages: A rare case of giant perivascular spaces in the midbrain manifesting as atypical parkinsonism**
P. Ferrer
- 193 **Editors' note: Optimal deep brain stimulation site and target connectivity for chronic cluster headache**
M. Alcauskas and S. Galetta
- 193 **Reader response: Optimal deep brain stimulation site and target connectivity for chronic cluster headache**
V.K. Gupta
- 194 **Author response: Optimal deep brain stimulation site and target connectivity for chronic cluster headache**
H. Akram, M. Matharu, and L. Zrinzo

Department

In the Next Issue of *Neurology*[®]



[Cover image](#)

An image from Denise Louis-Bar's 1941 *Confinia Neurologica* report demonstrates ocular telangiectasias in a child. Colorized by Cindy Abair, *Neurology* Senior Graphics Editor.

[See page 175](#)

Neurology[®]

91 (4)

Neurology 2018;91:e382-194

This information is current as of January 1, 2018

Updated Information & Services

including high resolution figures, can be found at:
<http://n.neurology.org/content/91/4.full>

Permissions & Licensing

Information about reproducing this article in parts (figures, tables) or in its entirety can be found online at:
http://www.neurology.org/about/about_the_journal#permissions

Reprints

Information about ordering reprints can be found online:
<http://n.neurology.org/subscribers/advertise>

Neurology® is the official journal of the American Academy of Neurology. Published continuously since 1951, it is now a weekly with 48 issues per year. Copyright . All rights reserved. Print ISSN: 0028-3878. Online ISSN: 1526-632X.

