

Neurology[®]

The most widely read and highly cited peer-reviewed neurology journal
The Official Journal of the American Academy of Neurology



Neurology Publish Ahead of Print

DOI: 10.1212/WNL.000000000206823

Teaching NeuroImage: Bilateral Internal Carotid Artery Stenosis Due to Aggressive Giant Cell Arteritis

Author(s):

Antonio Doncel-Moriano Cubero, MD¹; Georgina Espigol, MD, PhD²; Arturo Renú, MD, PhD³

Corresponding Author:

Arturo Renú, arenu@clinic.cat

Affiliation Information for All Authors: 1. Department of Neuroscience, Hospital Clinic, Barcelona, Spain; 2. Department of Autoimmune Diseases, Hospital Clinic, University of Barcelona, Institut d'Investigacions Biomèdiques August Pi i Sunyer (IDIBAPS), Barcelona, Spain; 3. Comprehensive Stroke Center, Department of Neuroscience, Hospital Clinic, University of Barcelona, Institut d'Investigacions Biomèdiques August Pi i Sunyer (IDIBAPS), Barcelona, Spain.

Equal Author Contribution:

Contributions:

Antonio Doncel-Moriano Cubero: Drafting/revision of the manuscript for content, including medical writing for content; Major role in the acquisition of data; Study concept or design; Analysis or interpretation of data

Georgina Espigol: Drafting/revision of the manuscript for content, including medical writing for content; Study concept or design; Analysis or interpretation of data

Arturo Renú: Drafting/revision of the manuscript for content, including medical writing for content; Study concept or design; Analysis or interpretation of data

Figure Count:

2

Table Count:

0

Search Terms:

[2] All Cerebrovascular disease/Stroke, [13] Other cerebrovascular disease/ Stroke, [132] Autoimmune diseases, [134] Vasculitis, [146] All Medical/Systemic disease

Acknowledgment:**Study Funding:**

The authors report no targeted funding

Disclosures:

The authors report no relevant disclosures.

Preprint DOI:**Received Date:**

2022-05-27

Accepted Date:

2022-12-02

Handling Editor Statement:

Submitted and externally peer reviewed. The handling editor was Associate Editor Roy Strowd III, MD, Med, MS.

An eighty-year-old man was admitted with sudden right eye vision loss secondary to acute ischemia of the optic nerve and subacute headache with ESR elevated (142mm/h). A diagnosis of giant cell arteritis (GCA) was made and the patient was started on methylprednisone (intravenous, 1g/d for 3 days) followed by oral prednisone (60 mg/day). Ten days later he was admitted to our stroke center with severe aphasia (NIHSS 9). CT-angiography revealed bilateral vertebral stenosis and bilateral internal carotid artery (ICA) stenosis in the ophthalmic segment (>90% stenosis) with extensive ischemic penumbra area on CT-perfusion (Figure 1). Angioplasty of the left-ICA was successfully performed with symptom improvement (Figure 1). Ultrasound-guided-biopsy confirmed GCA (Figure 2). The patient continued prednisone (60mg/day), methotrexate (20mg/week) and aspirin (100mg/day). GCA commonly presents with vertebral stenosis and ICA stenosis¹. Intracerebral stenosis is a rare complication of CGA and is commonly refractory to medical therapy. Angioplasty is a potential rescue strategy to prevent ischemic complications².

<http://links.lww.com/WNL/C575>

REFERENCES:

- 1-Cox BC, Fulgham JR, Klaas JP. Recurrent Stroke in Giant Cell Arteritis Despite Immunotherapy. *Neurologist*. 2019;24:e139–e141. doi: 10.1097/NRL.0000000000000237
- 2-Caton MT, Mark IT, Baker A et al. Endovascular treatment for intracranial giant cell arteritis with angioplasty, stenting, and intra-arterial calcium channel blockers. *J NeuroIntervent Surg*. 2021;13:A1-A156.

Figure-1. Angiography (A-F): moderate stenosis of the right carotid artery, white arrow (frontal, A; lateral, B); severe stenosis of the left internal carotid artery, yellow arrow (frontal, C; lateral, D); left internal carotid artery post angioplasty without residual stenosis, red arrow (frontal, E; lateral, F). CT perfusion (G-H): ischemic penumbra in the left hemisphere, blue arrows (time to peak, G; cerebral blood volume, H).

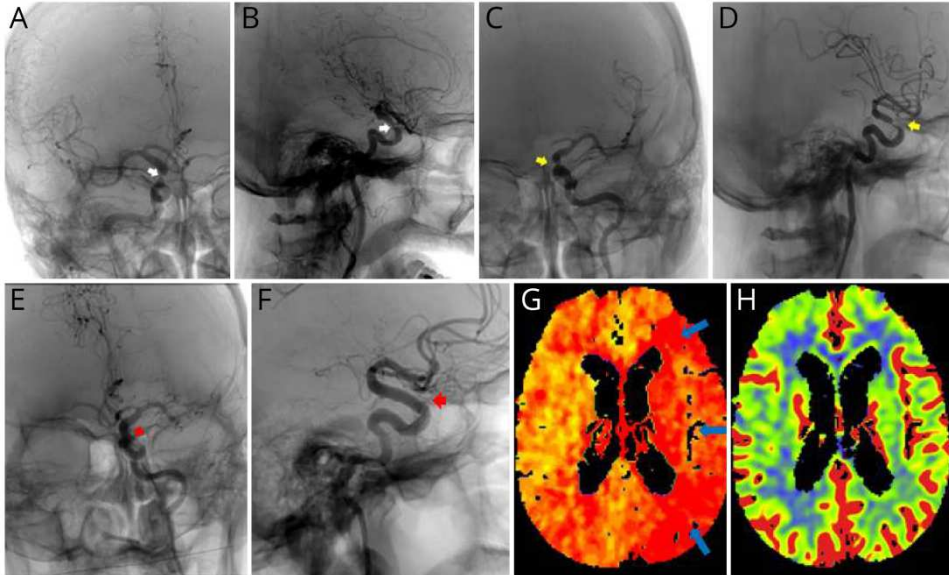
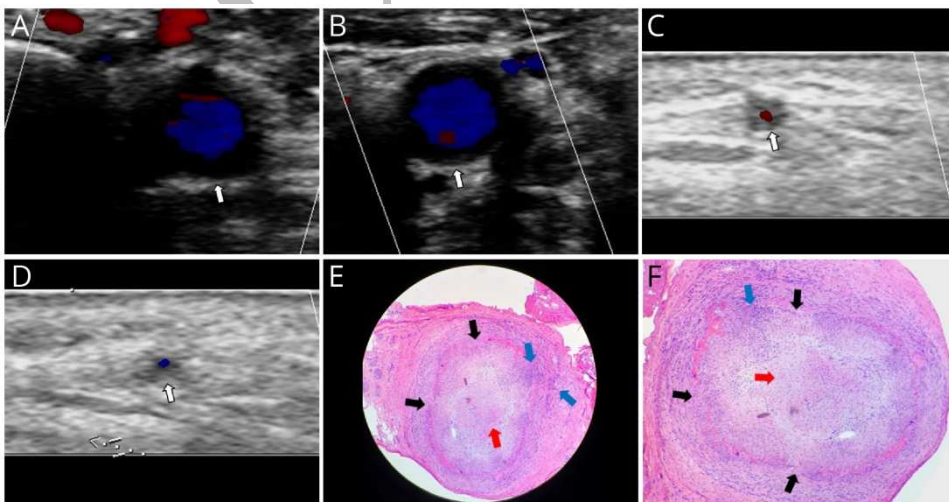


Figure-2: Doppler sonography A-D. Hypoechoic halo (white arrows) secondary to mural inflammation and mural edema in the right common carotid artery (transversal, A), left common carotid artery (transversal, B) and in both temporal arteries (right C and left D). Left temporal artery biopsy E-F. Intimal hyperplasia (red arrow), elastic internal lamina disruption (black arrow) and inflammatory infiltrate with lymphocytes and histiocytes (blue arrow).



Neurology[®]

Teaching NeuroImage: Bilateral Internal Carotid Artery Stenosis Due to Aggressive Giant Cell Arteritis

Antonio Doncel-Moriano Cubero, Georgina Espigol and Arturo Renú
Neurology published online December 23, 2022
DOI 10.1212/WNL.0000000000206823

This information is current as of December 23, 2022

Updated Information & Services	including high resolution figures, can be found at: http://n.neurology.org/content/early/2022/12/22/WNL.0000000000206823.citation.full
Subspecialty Collections	This article, along with others on similar topics, appears in the following collection(s): All Cerebrovascular disease/Stroke http://n.neurology.org/cgi/collection/all_cerebrovascular_disease_stroke All Medical/Systemic disease http://n.neurology.org/cgi/collection/all_medical_systemic_disease Autoimmune diseases http://n.neurology.org/cgi/collection/autoimmune_diseases Other cerebrovascular disease/ Stroke http://n.neurology.org/cgi/collection/other_cerebrovascular_disease_stroke Vasculitis http://n.neurology.org/cgi/collection/vasculitis
Permissions & Licensing	Information about reproducing this article in parts (figures, tables) or in its entirety can be found online at: http://www.neurology.org/about/about_the_journal#permissions
Reprints	Information about ordering reprints can be found online: http://n.neurology.org/subscribers/advertise

Neurology® is the official journal of the American Academy of Neurology. Published continuously since 1951, it is now a weekly with 48 issues per year. Copyright © 2022 American Academy of Neurology. All rights reserved. Print ISSN: 0028-3878. Online ISSN: 1526-632X.

