

---

**Neurology Publish Ahead of Print**  
**DOI: 10.1212/WNL.000000000206756**

## Teaching Video NeuroImage: Reverse Ocular Bobbing as a Presenting Feature of Brainstem Cavernoma

**Author(s):**

Kavindra Singh, MBBS, MS, MCh<sup>1</sup>; Pravin Salunke, MBBS, MS, MCh<sup>2</sup>

**Corresponding Author:**

Kavindra Singh, [singh.kavindra8@gmail.com](mailto:singh.kavindra8@gmail.com)

**Affiliation Information for All Authors:** 1. Department of Neurosurgery, Post Graduate Institute of Medical Education and Research, Chandigarh, India; 2. Department of Neurosurgery, Post Graduate Institute of Medical Education and Research, Chandigarh, India

**Equal Author Contribution:**

All authors contributed equally to this work.

**Contributions:**

Kavindra Singh: Drafting/revision of the manuscript for content, including medical writing for content; Major role in the acquisition of data

Pravin Salunke: Drafting/revision of the manuscript for content, including medical writing for content; Study concept or design; Analysis or interpretation of data

*Neurology*<sup>®</sup> Published Ahead of Print articles have been peer reviewed and accepted for publication. This manuscript will be published in its final form after copyediting, page composition, and review of proofs. Errors that could affect the content may be corrected during these processes.

**Figure Count:**

1

**Table Count:**

0

**Search Terms:**

[ 14 ] All Clinical Neurology, [ 46 ] All Education, [ 186 ] All Neuro-ophthalmology, [ 187 ] Ocular motility, [ 197 ] Oscillopsia

**Acknowledgment:****Study Funding:**

The authors report no targeted funding

**Disclosures:**

The authors report no relevant disclosures.

**Preprint DOI:****Received Date:**

2022-08-22

**Accepted Date:**

2022-11-16

**Handling Editor Statement:**

Submitted and externally peer reviewed. The handling editor was Whitley Aamodt, MD, MPH.

A 21 year-old male presented with oscillopsia, repetitive eye blinking and headache for 20 days. He had intact vision with normal pupillary reaction. Although the horizontal and vertical gazes were intact, there were abnormal conjugate vertical movements with quick up phase followed by slow return to midposition suggestive of reverse ocular bobbing (video 1). Bobbing was present in all directions of gaze and was associated with synkinetic lid movements. Imaging suggested a dorsal pontine cavernoma (Figure). The patient opted for radiosurgery. Omnipause neurons in dorsal pons tonically inhibit the riMLF burst neurons (centre for vertical saccades) which also indirectly stimulates levator subnucleus<sup>1</sup>. Damage to omnipause neurons or connections may cause reverse ocular bobbing with synkinetic lid movements. Unlike ocular bobbing, the horizontal gaze is intact due to uninvolved PPRF<sup>2</sup>. Interestingly, reverse ocular bobbing has been previously reported in cases of metabolic encephalopathy, but is rarely associated with a structural lesion.

WNL-2022-201554\_slides ----<http://links.lww.com/WNL/C579>WNL-2022-201554\_vid1 ---- <http://links.lww.com/WNL/C580>

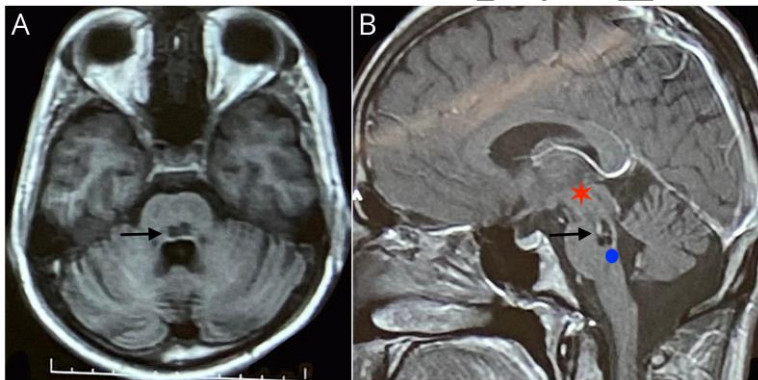
References:

1. Brazis PW, The localization of lesions affecting the ocular motor system. In: Brazis PW, Masdeu JC, Biller J (eds). Localization in clinical Neurology, 6<sup>th</sup> edition, Lippinkott Williams & Wilkins; 2011: 173-304
2. Munakomi S, Thapa L. Seesaw-Pattern Ocular Bobbing in a Patient With Pontine Bleed. JAMA Neurol. 2019 Mar 1;76(3):362-363.doi:10.1001/jamaneurol.2018.3853

**Figure 1-Showing axial and sagittal MRI images delineating a dorsal pontine cavernoma**

**Figure A-** T1 weighted axial MRI sequence showing a hypointense lesion in dorsal pons (marked with black arrow)

**Figure B-** T1W+C sagittal MRI sequence depicting a lesion (marked with black arrow) with faint contrast enhancement at dorsal pontomesencephalic junction. Red star represents riMLF, which has the excitatory burst neurons for vertical saccades and blue circle at dorsal pons approximates location of omnipause cells lying in the nucleus raphe interpositus, which is located in the midline at the level of abducens nucleus. The connections between riMLF and omnipause neurons are damaged leading to reverse bobbing



**Video-** Video demonstrating intact gaze in all directions with synchronised upward movement followed by return to mid-position associated with lid synkinesis.

# Neurology®

## Teaching Video NeuroImage: Reverse Ocular Bobbing as a Presenting Feature of Brainstem Cavernoma

Kavindra Singh and Pravin Salunke

*Neurology* published online December 29, 2022

DOI 10.1212/WNL.0000000000206756

**This information is current as of December 29, 2022**

<b>Updated Information &amp; Services</b>	including high resolution figures, can be found at: <a href="http://n.neurology.org/content/early/2022/12/29/WNL.0000000000206756.citation.full">http://n.neurology.org/content/early/2022/12/29/WNL.0000000000206756.citation.full</a>
<b>Subspecialty Collections</b>	This article, along with others on similar topics, appears in the following collection(s): <b>All Clinical Neurology</b> <a href="http://n.neurology.org/cgi/collection/all_clinical_neurology">http://n.neurology.org/cgi/collection/all_clinical_neurology</a> <b>All Education</b> <a href="http://n.neurology.org/cgi/collection/all_education">http://n.neurology.org/cgi/collection/all_education</a> <b>All Neuro-ophthalmology</b> <a href="http://n.neurology.org/cgi/collection/all_neuroophthalmology">http://n.neurology.org/cgi/collection/all_neuroophthalmology</a> <b>Ocular motility</b> <a href="http://n.neurology.org/cgi/collection/ocular_motility">http://n.neurology.org/cgi/collection/ocular_motility</a> <b>Oscillopsia</b> <a href="http://n.neurology.org/cgi/collection/oscillopsia">http://n.neurology.org/cgi/collection/oscillopsia</a>
<b>Permissions &amp; Licensing</b>	Information about reproducing this article in parts (figures, tables) or in its entirety can be found online at: <a href="http://www.neurology.org/about/about_the_journal#permissions">http://www.neurology.org/about/about_the_journal#permissions</a>
<b>Reprints</b>	Information about ordering reprints can be found online: <a href="http://n.neurology.org/subscribers/advertise">http://n.neurology.org/subscribers/advertise</a>

*Neurology*® is the official journal of the American Academy of Neurology. Published continuously since 1951, it is now a weekly with 48 issues per year. Copyright © 2022 American Academy of Neurology. All rights reserved. Print ISSN: 0028-3878. Online ISSN: 1526-632X.

