

---

**Neurology Publish Ahead of Print**

**DOI: 10.1212/WNL.000000000206773**

## Clinical Reasoning: A 23-Year-Old Man With Progressive Asymmetric Weakness and Numbness

**Author(s):**

Emma H Kaplan, MD<sup>1</sup>; Kaveh Torabian, MS<sup>2</sup>; Camille V Edwards, MD<sup>1</sup>; Michelle C. Kaku, MD<sup>1</sup>; Pria Anand, MD<sup>1</sup>; K. H. Vincent Lau, MD<sup>1</sup>

**Corresponding Author:**

Emma H Kaplan, emma.kaplan@bmc.org

**Affiliation Information for All Authors:** 1. Boston University School of Medicine; 2. Mass General Brigham Hospital

**Equal Author Contribution:**

Dr. Emma H. Kaplan and Mr. Kaveh Torabian contributed equally to this work as first authors.

**Contributions:**

Emma H Kaplan: Drafting/revision of the manuscript for content, including medical writing for content; Major role in the acquisition of data; Study concept or design; Analysis or interpretation of data

Kaveh Torabian: Drafting/revision of the manuscript for content, including medical writing for content; Major role in the acquisition of data; Study concept or design; Analysis or interpretation of data

Camille V Edwards: Drafting/revision of the manuscript for content, including medical writing for content

Michelle C. Kaku: Drafting/revision of the manuscript for content, including medical writing for content

Pria Anand: Drafting/revision of the manuscript for content, including medical writing for content

K. H. Vincent Lau: Drafting/revision of the manuscript for content, including medical writing for content; Major role in the acquisition of data; Study concept or design; Analysis or interpretation of data

*Neurology*® Published Ahead of Print articles have been peer reviewed and accepted for publication. This manuscript will be published in its final form after copyediting, page composition, and review of proofs. Errors that could affect the content may be corrected during these processes.

**Figure Count:**

1

**Table Count:**

1

**Search Terms:**

[ 285 ] EMG, [ 131 ] All Immunology, [ 183 ] Chronic inflammatory demyelinating polyneuropathy

**Acknowledgment:****Study Funding:**

The authors report no targeted funding

**Disclosures:**

The authors report no relevant disclosures.

**Preprint DOI:****Received Date:**

2022-07-01

**Accepted Date:**

2022-11-17

**Handling Editor Statement:**

Submitted and externally peer reviewed. The handling editor was Ariel Lyons-Warren, MD, PhD.

**Abstract**

We report a case of a 23-year-old man who presented with progressive asymmetric weakness and numbness in his distal extremities over four months, with initial symptoms starting days after a coronavirus 2019 (COVID-19) vaccine booster. Initial neurologic exam was notable for distal weakness of both upper and lower extremities that was more pronounced on the left, complete areflexia, and decreased distal sensation to pinprick and vibration without loss of proprioception. Nerve conduction studies demonstrated a generalized, non-length-dependent, sensorimotor, demyelinating polyneuropathy, with conduction block seen in multiple compound muscle action potentials. Sensory nerve action potentials were normal in absolute terms, but had asymmetric amplitudes.

Based on the patient's nerve conduction studies, he was diagnosed with a specific immune-mediated neuromuscular disorder. He was started on intravenous immunoglobulin, but within days of the first infusions experienced a rare and potentially life-threatening complication. He received appropriate treatment and was started on alternative immunotherapy, after which his symptoms improved.

Our case exemplifies the features of a specific subtype of a more common immune-mediated neuromuscular diagnosis with unique elements of history, examination, and nerve conduction studies that required interpretation in the clinical context. We also discuss a rare side effect of a commonly used immunotherapy and its risk factors, and comment on the likelihood that this diagnosis may be related to a preceding COVID-19 vaccine booster.

## **Section 1**

A 23-year-old man presented with numbness, tingling, and weakness in his extremities progressing over four months. He initially noticed left thumb numbness and tingling that spread throughout his hand, followed a month later by sensory changes in both legs and left leg weakness. Previously a lacrosse player, he lost the ability to run. He denied neck or low back pain. He denied any preceding illness, but had received the coronavirus 2019 (COVID-19) Moderna vaccine booster three days prior to symptom onset.

His initial neurologic examination was notable for distal weakness of both upper and lower extremities, more pronounced on the left. Shoulder abduction, elbow extension and flexion, and wrist extension and flexion strength were graded 5/5 bilaterally using the Medical Research Council (MRC) scale; finger abduction (interosseous) and thumb abduction (abductor pollicis brevis) were 4/5 bilaterally; hip flexion, knee extension and flexion were 5/5 bilaterally;

ankle dorsiflexion was 4/5 bilaterally; ankle plantarflexion was 5/5 bilaterally; toe extension was 1/5 on the left and 4/5 on the right; and toe flexion was 5/5 bilaterally. Sensation to pinprick was decreased distally in both upper and lower extremities with 8 seconds timed vibration sensation at bilateral great toes, while proprioception was intact. Romberg's sign was absent. Reflexes were absent throughout. He could march on his toes but not on his heels.

### Questions for Consideration

1. Where along the neuromuscular axis could this process localize?
2. What is the best next diagnostic step?

### **Section 2**

The combination of motor weakness, sensory abnormalities, and areflexia suggests a disorder of the lower motor neurons, which may localize to the nerve roots, plexuses, or peripheral nerves. Simultaneous upper and lower extremity involvement suggests a diffuse process and narrows the localization to the peripheral nerves, with a non-length-dependent pattern suggestive of an inflammatory polyneuropathy. The next best diagnostic step is to obtain nerve conduction studies (NCS), which may help differentiate between a demyelinating and axonal neuropathy and elucidate further patterns such as uniformity or symmetry. These were performed and are summarized in the **Table**.

### Questions for Consideration

1. What is the interpretation of these NCS?

### Section 3

NCS showed normal sensory nerve action potentials (SNAP) in absolute terms, but amplitudes were asymmetric in two nerves (sural: right 11.6uV and left 21.5uV; median: right 18.4uV and left 41.0uV). Compound muscle action potentials (CMAP) had slowed conduction velocities in multiple nerves, several with associated conduction block. The peroneal-extensor digitorum brevis CMAP had particularly slowed conduction velocities with conduction block (Figure). The left median and tibial F-wave latencies were prolonged. The needle electromyography portion of the electrodiagnostic study was normal.

Although the NCS abnormalities were much more striking in motor nerves, the asymmetric SNAPs along with the patient's sensory symptoms and deficits on examination suggest sensorimotor involvement. Taken together, NCS demonstrated a generalized, non-length-dependent, sensorimotor, demyelinating polyneuropathy.

#### Questions for Consideration

1. What is the differential diagnosis for a demyelinating polyneuropathy?
2. What are the best next steps in evaluation?

### Section 4

The differential diagnosis for subacute or chronic sensory and motor demyelinating neuropathy includes CIDP and its variants, paraproteinemic neuropathy, inherited polyneuropathies, and neuropathy secondary to medication exposures. This is a short list compared to that for axonal neuropathies, which includes numerous metabolic, toxic, infectious, and other etiologies.<sup>1</sup> Regarding the possibility of CIDP, the patient's NCS met diagnostic

criteria for multifocal CIDP in the 2021 revised European Academy of Neurology/Peripheral Nerve Society guidelines.<sup>2</sup> Specifically, motor conduction criteria for demyelination was seen in at least two nerves and in more than one limb (in this case, right ulnar and peroneal CMAP motor conduction blocks among other criteria) and sensory conduction abnormalities were seen in at least two nerves (in this case, left median and right sural SNAPs). The initial approach to a demyelinating neuropathy is to complete a detailed clinical history encompassing toxic exposures, family history, and a thorough review of systems. This is followed by laboratory studies corresponding to the differential diagnosis.<sup>1</sup>

In this case, the patient did not have toxic exposures, a contributory family history, or systemic symptoms suggestive of a plasma cell dyscrasia. He had unremarkable serum electrophoresis (SPEP), immunofixation (IFE), free light chains, anti-MAG antibodies, and vascular endothelial growth factor. Given the non-contributory history and normal serum studies, CIDP or a CIDP variant was strongly considered. To further evaluate for this possibility, cerebrospinal fluid (CSF) studies were obtained and revealed a borderline protein of 45mg/dL (normal 15-45 mg/dl) with no pleocytosis.

#### Questions for Consideration

1. Based on specific elements of history, examination, and NCS findings, which CIDP variant is most likely?

#### **Section 5**

CIDP subtypes include typical CIDP as characterized classically by symmetric and proximal and distal weakness, acute CIDP, sensory CIDP, chronic immune sensory

polyradiculopathy (CISP), motor CIDP, multifocal acquired demyelinating sensory and motor neuropathy (MADSAM), and distal acquired demyelinating and symmetric (DADS) neuropathy.<sup>3</sup> Our patient's neuropathy was best characterized as sensorimotor, asymmetric, and subacute. These elements were most consistent with a diagnosis of MADSAM. It should be noted that if NCS were interpreted without the context of the patient's history and examination, the predominant motor involvement may suggest multifocal motor neuropathy (MMN), a disorder distinct from CIDP characterized by asymmetric, purely motor nerve dysfunction.<sup>3</sup>

The patient was started on 2g/kg of intravenous immunoglobulins (IVIg) administered over two days. Three days after the initial dose, he noticed dark-colored urine and fatigue. Laboratory studies five days after IVIg was notable for hemoglobin 12.3g/dL, below his baseline of 15g/dL. Three days later, repeat hemoglobin was 10.6g/dL. Aspartate transaminase (AST) and alanine transaminase (ALT) were found to be elevated at 54 and 107 U/L, respectively.

Question for Consideration:

1. Which adverse effect of IVIg is the patient most likely experiencing?
2. What are the next best steps to confirm this suspicion?
3. How can this adverse effect be managed?

**Section 6**

Dark-colored urine along with downtrending hemoglobin following IVIg administration suggests hemolytic anemia, a rare complication. In this case, additional studies supported this diagnosis, including an elevated reticulocyte index (2.2%), elevated indirect bilirubin (0.8mg/dL), and low haptoglobin (<8 mg/dL). Lactate dehydrogenase was normal and urinalysis

was unremarkable, but these negative studies did not exclude the diagnosis. Direct antiglobulin test (DAT) was negative. Blood type was AB negative, Rh negative. With the trough in hemoglobin, the patient received high-dose steroids, and the long-term treatment was switched to subcutaneous immunoglobulin. He did not experience further adverse effects, and had gradual improvement in motor strength and sensory symptoms.

## Discussion

MADSAM is a CIDP variant characterized by gradually progressive and asymmetric weakness and numbness. Electrodiagnostic studies demonstrate a demyelinating sensorimotor polyneuropathy with multifocal nerve involvement. Approximately three-fourths of patients have albuminocytologic dissociation on CSF studies. Similar to other CIDP variants, it may be treated with immunotherapy including IVIg, plasmapheresis, and corticosteroids.<sup>3</sup> Although some studies describe the course of MADSAM as less debilitating, symptoms may be less responsive to first-line immunotherapy compared to typical CIDP.<sup>4</sup>

Hemolytic anemia is a rare complication of IVIg, with an estimated prevalence of 1.6%.<sup>5</sup> The mechanism is thought to be a reaction caused by isohemagglutinins (anti-A/B antibodies) incompatible with the patient's blood group passively transferred during IVIg transfusion.<sup>6</sup> This complication is most common in non-O blood group patients, hypothetically due to their inability to neutralize the isohemagglutinins, and with cumulative doses of 2g/kg or above in IVIG-naïve patients.<sup>7</sup> Our patient had both risk factors, but his Direct Antiglobulin Test (DAT) was notably negative, a finding in 12.5% of cases of hemolytic anemia with unclear mechanism.<sup>8</sup> Of note, no studies have investigated whether the risk of hemolytic anemia depends on the number of days over which doses are administered. The national IVIg shortage<sup>9</sup> has necessitated that clinicians



occasionally use shorter courses of IVIg at higher daily doses to reduce waste from rounding; further study is needed to determine whether this increases the rates of adverse effects. IVIg-mediated hemolysis can be self-limiting, only requiring observation. However, in severe cases, patients may require intravenous fluids and transfusions. IVIg infusion should be stopped and the batch of IVIg may be quarantined.<sup>9</sup>

Our patient received the COVID-19 Moderna vaccine booster three days prior to symptom onset, raising the possibility of an adverse vaccine reaction. A recent *Neurology* article discussing Guillain-Barre syndrome (GBS) and the COVID-19 Vaccine Clinical Trial<sup>10</sup> argued that the temporal association between vaccination and symptom onset does not imply causality, given the very large number of individuals who received COVID vaccinations in the first months of their availability. It is also possible that a vaccination unmasks an underlying, previously asymptomatic autoimmune disorder rather than cause it.<sup>11</sup> Similarly, one should be cautious in attributing new diagnoses of CIDP to COVID vaccinations, the subject of several case reports<sup>12, 13</sup> and Vaccine Adverse Event Reporting System entries.<sup>14</sup> Although available data are limited, observational studies suggest a higher risk of an inflammatory demyelinating polyneuropathy after SARS-CoV-2 infection compared with vaccination, in consensus with prior studies demonstrating the same for GBS and influenza.<sup>15</sup> As such, neurologists should continue to advocate for their patients to be fully vaccinated for COVID-19 and other infections.

## Appendix 1: Authors

Name	Location	Contribution
Emma H. Kaplan, MD*	Boston University School of Medicine, Boston MA	Drafted and revised the manuscript for content, analyzed and interpreted the data.
Kaveh Torabian, MS*	Massachusetts General Brigham, Boston MA	Drafted and revised the manuscript for content, analyzed and interpreted the data
Camille Edwards, MD	Boston University School of Medicine, Boston MA	Revised the manuscript for content
Pria Anand, MD	Boston University School of Medicine, Boston MA	Revised the manuscript for content
Michelle C. Kaku, MD	Boston University School of Medicine, Boston MA	Revised the manuscript for content

K. H. Vincent Lau, MD	Boston University School of Medicine, Boston MA	Revised the manuscript for content, had major role in acquisition of the data, analyzed and interpreted the data
-----------------------	--	--

\*Contributed equally

ACCEPTED

## References

1. Siao P, Kaku M. A Clinician's Approach to Peripheral Neuropathy. *Semin Neurol*. Oct 2019;39(5):519-530. doi:10.1055/s-0039-1694747
2. Van den Bergh PYK, van Doorn PA, Hadden RDM, et al. European Academy of Neurology/Peripheral Nerve Society guideline on diagnosis and treatment of chronic inflammatory demyelinating polyradiculoneuropathy: Report of a joint Task Force-Second revision. *J Peripher Nerv Syst*. Sep 2021;26(3):242-268.
3. Gwathmey K. Chronic Inflammatory Demyelinating Polyradiculoneuropathy and Its Variants. *Continuum (Minneap Minn)*. Oct 2020;26(5):1205-1223.
4. Kuwabara S, Iose S, Mori M, et al. Different electrophysiological profiles and treatment response in 'typical' and 'atypical' chronic inflammatory demyelinating polyneuropathy. *J Neurol Neurosurg Psychiatry*. Oct 2015;86(10):1054-9.
5. Daw Z, Padmore R, Neurath D, et al. Hemolytic transfusion reactions after administration of intravenous immune (gamma) globulin: a case series analysis. *Transfusion*. Aug 2008;48(8):1598-601.
6. Flegel WA. Pathogenesis and mechanisms of antibody-mediated hemolysis. *Transfusion*. Jul 2015;55 Suppl 2(0):S47-58.
7. Berard R, Whittemore B, Scuccimarri R. Hemolytic anemia following intravenous immunoglobulin therapy in patients treated for Kawasaki disease: a report of 4 cases. *Pediatr Rheumatol Online J*. Apr 16 2012;10(1):10.
8. Pendergrast J, Armali C, Callum J, et al. A prospective observational study of the incidence, natural history, and risk factors for intravenous immunoglobulin-mediated hemolysis. *Transfusion*. Apr 2021;61(4):1053-1063.

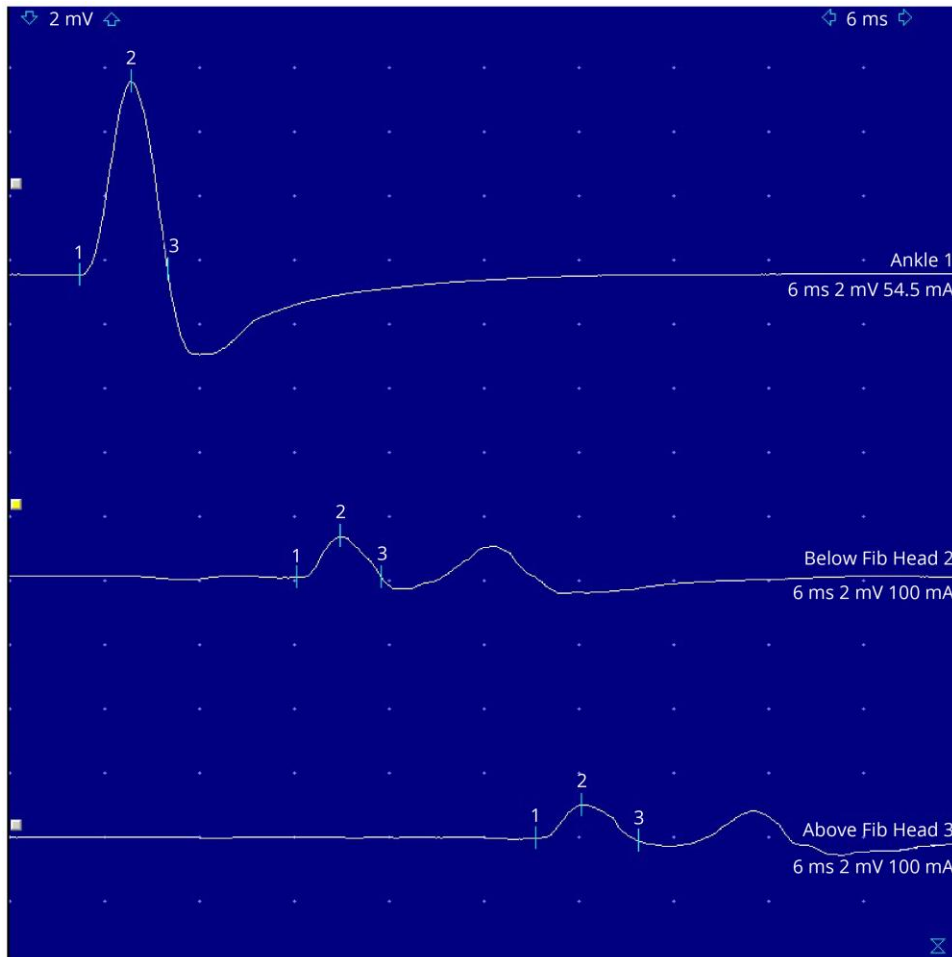
9. Administration USFaD. Information About Immune Globulin (Human) Product Shortage. U.S. Food and Drug Administration. Accessed June 1, 2022. <https://www.fda.gov/vaccines-blood-biologics/safety-availability-biologics/information-about-immune-globulin-human-product-shortage>
10. Márquez Loza AM, Holroyd KB, Johnson SA, Pilgrim DM, Amato AA. Guillain- Barré Syndrome in the Placebo and Active Arms of a COVID-19 Vaccine Clinical Trial: Temporal Associations Do Not Imply Causality. *Neurology*. Apr 6 2021.
11. Van Looy E, Veenker L, Steyaert A, Leenders J, Malfroid G, De Cauwer H. COVID-19-induced exacerbation of chronic inflammatory demyelinating polyneuropathy. *J Neurol*. Sep 2021;268(9):3129-3131.
12. Singh S, Sanna F, Adhikari R, Akella R, Gangu K. Chronic Inflammatory Demyelinating Polyneuropathy Post-mRNA-1273 Vaccination. *Cureus*. Apr 2022;14(4):e24528.
13. de Souza A, Oo WM, Giri P. Inflammatory demyelinating polyneuropathy after the ChAdOx1 nCoV-19 vaccine may follow a chronic course. *J Neurol Sci*. May 15 2022;436:120231.
14. Services USDoHaH. VAERS Vaccine Adverse Event Reporting System. Accessed 8/25/2022, 2022. <https://vaers.hhs.gov/>
15. Patone M, Handunnetthi L, Saatci D, et al. Neurological complications after first dose of COVID-19 vaccines and SARS-CoV-2 infection. *Nature Medicine*. Dec 2021;27(12):2144-2153.

**Table:** Nerve Conduction Studies. ADM: abductor digiti minimi; APB: abductor pollicis brevis; EDB: extensor digitorum brevis, FHB: flexor hallucis brevis; \*abnormal

Sensory Nerve Conduction Studies								
Nerve / Sites	Rec. Site	Dist	Peak	Amp.	Vel.	Temp.		
		cm	ms	µV	m/s	°C		
<b>L Median</b>								
Wrist	Digit 2	14.5	3.5	*18.4	51.6	34.7		
<b>L Ulnar</b>								
Wrist	Digit 5	14	3.2	22.3	54.9	33.9		
<b>L Radial</b>								
Forearm	Snuff box	10	2.1	26.1	58.2	32.6		
<b>L Sural</b>								
Post leg	Lat Mall	14	3.3	21.5	53.8	32.6		
<b>L Superficial peroneal</b>								
Lat leg	Ankle	14	3.6	15.2	50.7	32		
<b>R Sural</b>								
Post leg	Lat Mall	14	3.9	*11.6	48.0	29.4		
<b>R Superficial peroneal</b>								
Lat leg	Ankle	11	3.3	18.3	44.9	29.3		
<b>R Radial</b>								
Forearm	Snuff box	10	2.3	26.9	58.2	33.1		
<b>R Median</b>								
Wrist	Digit 2	15	3.8	41.0	61.3	33.4		
<b>R Ulnar</b>								
Wrist	Digit 5	13	3.4	30.8	49.9	33.5		
Motor Nerve Conduction Studies								
Nerve / Sites	Rec. Site	Dist.	Lat.	Amp.	Area	Dur.	Vel.	Temp.
		cm	ms	mV	mVms	ms	m/s	°C
<b>L Median - APB</b>								
Wrist	APB	6	3.0	10.9	39.6	6.5		32.4
Elbow w/MGA		27	8.7	*7.7	37.6	11.0	47.6	32.4
<b>L Ulnar - ADM</b>								
Wrist	ADM	6	3.6	12.8	36.5	6.8		32.2
B.Ulnar Gr		22.5	8.1	*8.8	27.7	7.8	50.8	32.4
A.Ulnar Gr		10	10.0	*7.9	26.3	7.7	51.9	32.4
Median stim at elbow	ADM		9.2	3.1	10.0	7.7		32.4
<b>L Peroneal - Tib Ant</b>								
Fib Head	Tib Ant	10	3.4	5.7	27.8	8.9		32.2
Pop Fossa		10	5.7	*2.9	14.3	9.4	43.6	32
<b>L Tibial - FHB</b>								
Med Mall	FHB	15.5	6.5	10.0	24.4	6.0		32
Pop Fossa		38	18.1	*1.1	3.5	5.6	*32.7	32.1
<b>L Peroneal - EDB</b>								
Ankle	EDB	9	4.6	6.0	17.4	5.6		32
Below Fib Head		32.5	19.5	*1.3	3.7	5.4	*21.9	32.1
Above Fib Head		10	23.1	*0.1	3.7	6.3	*27.4	32.2
<b>L Tibial - AH</b>								
Med Mall	AH	14	5.9	8.0	25.0	7.9		31
Pop Fossa		41	18.1	*2.1	8.1	8.4	*33.6	31
<b>R Median - APB</b>								
Wrist	APB	6	3.0	12.3	44.3	6.2		35.6
Elbow		26.5	9.0	*8.4	34.9	8.2	44.2	35.4
<b>R Ulnar - ADM</b>								
Wrist	ADM	6	2.5	9.7	26.2	6.2		31.9
B.Ulnar Gr		21.5	7.0	*3.4	13.3	7.6	47.4	31.6
A.Ulnar Gr		10	8.9	*3.4	12.8	7.9	53.3	31.6
<b>R Peroneal - EDB</b>								
Ankle	EDB	9	3.8	5.0	18.1	6.3		
Below Fib Head		36	11.2	*4.6	17.3	7.3	48.7	
Above Fib Head		10	13.2	*0.2	0.7	10.1	50.5	
<b>R Tibial - AH</b>								
Med Mall	AH	14	5.8	7.7	33.1	11.2		
Pop Fossa		38	14.9	*2.2	10.1	13.3	41.5	
F Wave								
Nerve	Fmin		Fmax		Max-Min			
		ms	ms		ms			
<b>L Median - APB</b>			*34.58		35.63		1.04	
<b>L Ulnar - ADM</b>			28.39		30.00		1.61	
<b>L Tibial - FHB</b>			*71.04		72.81		1.77	

## Figure Caption

**Figure: Left peroneal compound muscle action potential recording at the extensor digitorum brevis, with conduction block between the ankle and fibular head.**



# Neurology<sup>®</sup>

## Clinical Reasoning: A 23-Year-Old Man With Progressive Asymmetric Weakness and Numbness

Emma H Kaplan, Kaveh Torabian, Camille V Edwards, et al.

*Neurology* published online December 29, 2022

DOI 10.1212/WNL.0000000000206773

**This information is current as of December 29, 2022**

<b>Updated Information &amp; Services</b>	including high resolution figures, can be found at: <a href="http://n.neurology.org/content/early/2022/12/29/WNL.0000000000206773.full">http://n.neurology.org/content/early/2022/12/29/WNL.0000000000206773.full</a>
<b>Subspecialty Collections</b>	This article, along with others on similar topics, appears in the following collection(s): <b>All Immunology</b> <a href="http://n.neurology.org/cgi/collection/all_immunology">http://n.neurology.org/cgi/collection/all_immunology</a> <b>Chronic inflammatory demyelinating polyneuropathy</b> <a href="http://n.neurology.org/cgi/collection/chronic_inflammatory_demyelinating_polyneuropathy">http://n.neurology.org/cgi/collection/chronic_inflammatory_demyelinating_polyneuropathy</a> <b>EMG</b> <a href="http://n.neurology.org/cgi/collection/emg">http://n.neurology.org/cgi/collection/emg</a>
<b>Permissions &amp; Licensing</b>	Information about reproducing this article in parts (figures, tables) or in its entirety can be found online at: <a href="http://www.neurology.org/about/about_the_journal#permissions">http://www.neurology.org/about/about_the_journal#permissions</a>
<b>Reprints</b>	Information about ordering reprints can be found online: <a href="http://n.neurology.org/subscribers/advertise">http://n.neurology.org/subscribers/advertise</a>

*Neurology*® is the official journal of the American Academy of Neurology. Published continuously since 1951, it is now a weekly with 48 issues per year. Copyright © 2022 American Academy of Neurology. All rights reserved. Print ISSN: 0028-3878. Online ISSN: 1526-632X.

