

Teaching Video NeuroImage: Oculomotor Apraxia as the Only Presentation of Diffuse Intrinsic Pontine Glioma

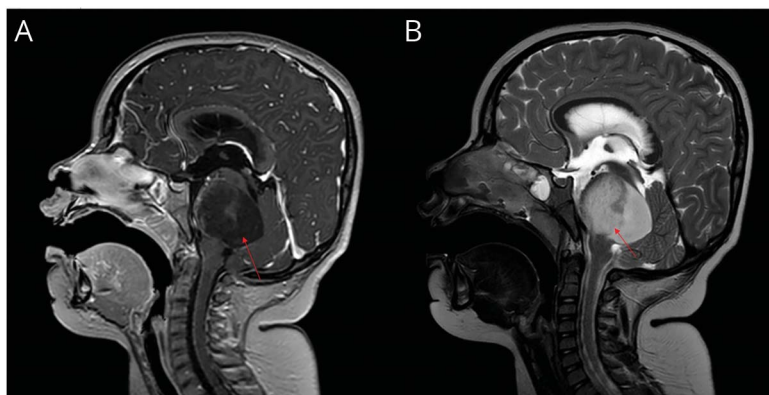
Farouq Thabet, MD, Mohammed Sawahreh, MD, Dana Thaher, MD, and Fatima Al Maadid, MD

Neurology® 2023;101:e854–e855. doi:10.1212/WNL.0000000000207376

Correspondence

Dr. Thabet
fthabit@gmail.com

Figure MRI of the Brain Showing Diffuse Intrinsic Pontine Glioma



MRI of the brain T1-weighted image (sagittal view) showing a mass centered in the pons (arrow) with significant expansion and mild extension to the midbrain as well as a posterior exophytic component obliterating the 4th ventricle leading to early hydrocephalus (A). T2-weighted image showing high signal intensity of the tumor (B).

A 5-year-old typically developing boy presented with a 4-week history of moving his head to follow objects due to inability to move his eyes side to side. His neurologic examination was normal except for this inability to voluntarily move his eyes horizontally, consistent with oculomotor apraxia (Video 1). MRI of the brain showed pontine mass suggestive of diffuse high-grade glioma (DIPG) (Figure). The patient underwent radiotherapy, and a ventriculoperitoneal shunt was placed for hydrocephalus.

In pediatric patients, oculomotor apraxia may be seen in ataxia with oculomotor apraxia, Cogan syndrome, Joubert syndrome, and ataxia telangiectasia. In our case, the brainstem tumor disrupted the structural connectivity between the frontal eye fields and oculomotor network including the pons, the superior colliculus, and caudate nucleus leading to oculomotor apraxia.¹

DIPG is an aggressive pediatric tumor with a median survival of 9–12 months. It classically presents with cranial nerve palsies, long tract signs, and ataxia.²

Author Contributions

F. Thabet: drafting/revision of the manuscript for content, including medical writing for content. Mohammed Sawahreh: drafting/revision of the manuscript for content, including medical writing for content. D. Thaher: major role in the acquisition of data. F.A. Maadid: major role in the acquisition of data.

Study Funding

The authors report no targeted funding.

From the Pediatric Neurology Division, Sidra Medicine, Doha, Qatar.

Go to [Neurology.org/N](https://www.neurology.org/N) for full disclosures. Funding information and disclosures deemed relevant by the authors, if any, are provided at the end of the article.

MORE ONLINE

 **Video**

Teaching slides

links.lww.com/WNL/C786

Disclosure

The authors report no relevant disclosures. Go to [Neurology.org/N](https://www.neurology.org/N) for full disclosures.

Publication History

Received by *Neurology* December 13, 2022. Accepted in final form March 20, 2023. Submitted and externally peer reviewed. The handling

editor was Resident & Fellow Section Deputy Editor Ariel Lyons-Warren, MD, PhD.

References

1. Helmchen C, Koch PJ, Girard G, Brüggemann N, Machner B, Sprenger A. NPTX1-related oculomotor apraxia: an intra-hemispheric disconnection disorder. *J Neurol*. 2022;269(7):3931-3936. doi:10.1007/s00415-022-11057-3
2. Hennika T, Becher OJ. Diffuse intrinsic pontine glioma: time for cautious optimism. *J Child Neurol*. 2016;31(12):1377-1385. doi:10.1177/0883073815601495

Neurology®

Teaching Video NeuroImage: Oculomotor Apraxia as the Only Presentation of Diffuse Intrinsic Pontine Glioma

Farouq Thabet, Mohammed Sawahreh, Dana Thaher, et al.
Neurology 2023;101:e854-e855 Published Online before print April 25, 2023
DOI 10.1212/WNL.0000000000207376

This information is current as of April 25, 2023

Updated Information & Services	including high resolution figures, can be found at: http://n.neurology.org/content/101/8/e854.full
References	This article cites 2 articles, 0 of which you can access for free at: http://n.neurology.org/content/101/8/e854.full#ref-list-1
Subspecialty Collections	This article, along with others on similar topics, appears in the following collection(s): All Neuro-ophthalmology http://n.neurology.org/cgi/collection/all_neuroophthalmology All Pediatric http://n.neurology.org/cgi/collection/all_pediatric MRI http://n.neurology.org/cgi/collection/mri Ocular motility http://n.neurology.org/cgi/collection/ocular_motility Primary brain tumor http://n.neurology.org/cgi/collection/primary_brain_tumor
Permissions & Licensing	Information about reproducing this article in parts (figures, tables) or in its entirety can be found online at: http://www.neurology.org/about/about_the_journal#permissions
Reprints	Information about ordering reprints can be found online: http://n.neurology.org/subscribers/advertise

Neurology® is the official journal of the American Academy of Neurology. Published continuously since 1951, it is now a weekly with 48 issues per year. Copyright © 2023 American Academy of Neurology. All rights reserved. Print ISSN: 0028-3878. Online ISSN: 1526-632X.

