

---

**Neurology Publish Ahead of Print**  
**DOI: 10.1212/WNL.000000000207824**

Teaching NeuroImages: Pneumorrhachis and paraplegia after spinal anesthesia

**Author(s):**

Fátima Hierro, Medical Doctor<sup>1</sup>; Joana Nunes<sup>2</sup>; Luis Fontão, Medical Doctor<sup>3</sup>

**Corresponding Author:**

Fátima Hierro, fatimashierro@gmail.com

**Affiliation Information for All Authors:** 1. Neuroradiology Department, Hospital Pedro Hispano; 2. Imagiology Department, Centro Hospitalar de Vila Nova de Gaia/Espinho; 3. Neurology Department, Centro Hospitalar de Entre Douro e Vouga

**Equal Author Contribution:**

**Contributions:**

Fátima Hierro: Drafting/revision of the manuscript for content and including medical writing for content; Major role in the acquisition of data; Study concept or design; Analysis or interpretation of data; Additional contributions (in addition to one or more of the above criteria)

Joana Nunes: Drafting/revision of the manuscript for content and including medical writing for content; Major role in the acquisition of data; Analysis or interpretation of data; Additional contributions (in addition to one or more of the above criteria)

Luis Fontão: Major role in the acquisition of data; Analysis or interpretation of data; Additional contributions (in addition to one or more of the above criteria)

**Figure Count:**

1

**Table Count:**

0

**Search Terms:**

[ 119 ] CT, [ 120 ] MRI, [ 252 ] All Spinal Cord, [ 17 ] Prognosis

**Acknowledgment:**

**Study Funding:**

The authors report no targeted funding.

**Disclosure:**

The authors report no relevant disclosures.

**Preprint DOI:**

**Received Date:**

2023-03-13

**Accepted Date:**

2023-07-10

**Handling Editor Statement:**

Submitted and externally peer reviewed. The handling editor was Resident and Fellow Deputy Editor Ariel Lyons-Warren, MD, PhD.

## **Pneumorrhachis and paraplegia after spinal anesthesia**

A 71-year-old female presented with paraplegia, absent deep tendon reflexes and a T10 sensory level nine hours after knee replacement surgery performed under spinal anesthesia. MR of the spine revealed intra and extra dural gas, termed pneumorrhachis (Figure 1A). Air in the extra and intra dural spaces led to canal stenosis (Figure 1B) and root clumping (Figure 1C) respectively. The patient was immediately started on high flow oxygen and then transferred for treatment in a hyperbaric chamber. Neurological deficits resolved and a CT scan (Figure 1D) revealed redistribution of the gas.

Pneumorrhachis, a complication of spinal or combined spinal and epidural anesthesia, occurs when air is injected using the loss-of-resistance technique<sup>1</sup> to identify the epidural space during catheter placement. A degenerative spine or previous spinal surgery can predispose to this complication.

Pneumorrhachis is asymptomatic in 90% of cases. The symptoms, when present, are neurologic deficits attributable to cord or root compression<sup>2</sup>. Treatment options include oxygen therapy or, in asymptomatic or mild cases, inpatient observation<sup>1,2</sup>.

ACCEPTED

## References

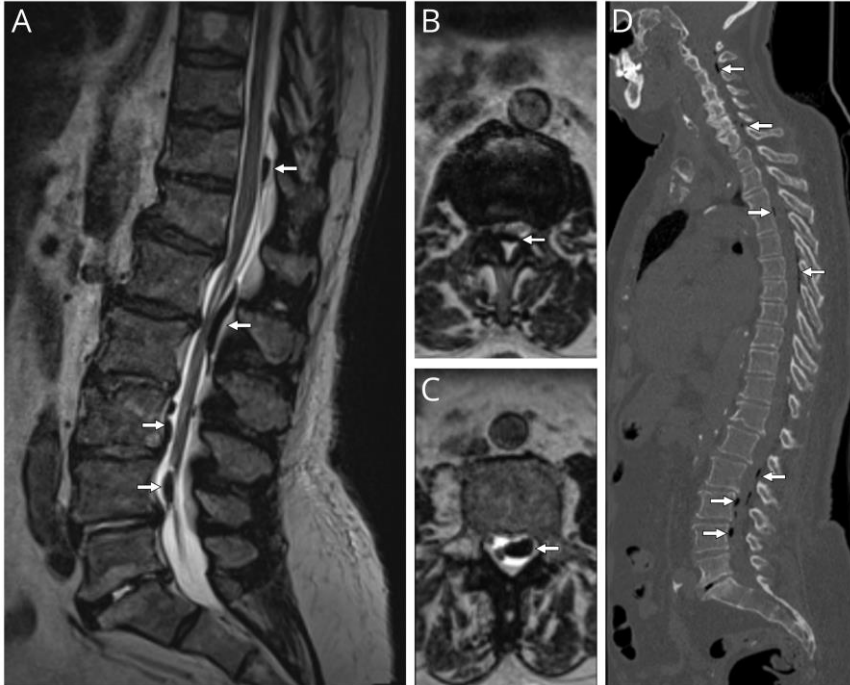
1. Reddi S, Honchar V, Robbins MS. Pneumocephalus associated with epidural and spinal anesthesia for labor. *Neurology* 2015;5:376-382.
2. Chaichana KL, Pradilla G, Witham TM, et al. The clinical significance of pneumorachis: A case report and review of the literature. *J Trauma* 2010;68:736-744.

**Note:** A translated version of this manuscript was provided to the patient, the objective of the publication was explained, and written informed consent was obtained via the “Consent-to-disclose” form.

ACCEPTED

**Figure:**

**Sagittal T2 TSE spine MRI showing gas collections in the spinal canal (A, arrows). Axial T2 TSE spine MRIs showing air present in (B) the extra dural space causing stenosis and (C) the intradural space leading to root clumping. Sagittal spine CT (D) showing gas collections distributed up to the level of C1.**



**MCQ**

Pneumorrhachis is a recognized complication of spinal anesthesia. What is the typical clinical presentation associated with this complication?

- A decreased level of consciousness.
- The condition is usually asymptomatic.
- Permanent focal deficits.
- This complication is often fatal.

# Neurology®

## Teaching NeuroImages: Pneumorrhachis and paraplegia after spinal anesthesia

Fátima Hierro, Joana Nunes and Luis Fontão  
*Neurology* published online August 18, 2023  
DOI 10.1212/WNL.0000000000207824

**This information is current as of August 18, 2023**

<b>Updated Information &amp; Services</b>	including high resolution figures, can be found at: <a href="http://n.neurology.org/content/early/2023/08/18/WNL.0000000000207824.citation.full">http://n.neurology.org/content/early/2023/08/18/WNL.0000000000207824.citation.full</a>
<b>Subspecialty Collections</b>	This article, along with others on similar topics, appears in the following collection(s): <b>All Spinal Cord</b> <a href="http://n.neurology.org/cgi/collection/all_spinal_cord">http://n.neurology.org/cgi/collection/all_spinal_cord</a> <b>CT</b> <a href="http://n.neurology.org/cgi/collection/ct">http://n.neurology.org/cgi/collection/ct</a> <b>MRI</b> <a href="http://n.neurology.org/cgi/collection/mri">http://n.neurology.org/cgi/collection/mri</a> <b>Prognosis</b> <a href="http://n.neurology.org/cgi/collection/prognosis">http://n.neurology.org/cgi/collection/prognosis</a>
<b>Permissions &amp; Licensing</b>	Information about reproducing this article in parts (figures, tables) or in its entirety can be found online at: <a href="http://www.neurology.org/about/about_the_journal#permissions">http://www.neurology.org/about/about_the_journal#permissions</a>
<b>Reprints</b>	Information about ordering reprints can be found online: <a href="http://n.neurology.org/subscribers/advertise">http://n.neurology.org/subscribers/advertise</a>

*Neurology*® is the official journal of the American Academy of Neurology. Published continuously since 1951, it is now a weekly with 48 issues per year. Copyright © 2023 American Academy of Neurology. All rights reserved. Print ISSN: 0028-3878. Online ISSN: 1526-632X.

